

# Area-dependent enlargement ratios of panoramic tomography depending on incorrect patient positioning and its significance for implant dentistry

## Part 2:

### Asymmetric Patient Positioning

German Gomez-Roman, Dr. med. dent.\*, Dieter Lukas, MSc.\*\*, Roman

Beniashvili, Dr. med. dent.\*\*\*, Willi Schulte, Prof., Dr. med. dent.\*\*\*\*

\* Associate Professor, Department of Prosthodontics, Dental School, University of Tübingen; and Former head of Collaborative Research Department A7 (Surgery of Dental Implants, Control and Documentation) of Special Research Project SFB175 "Implantology", (German Society of Research), Oslanderstr. 2-8, D-72076 Tübingen, Germany, Fax No. ++49 7071 293982

\*\*Research Fellow, Clinic of Oral and Maxillofacial Surgery, Dental School, Eberhard-Karl-University, Oslanderstr. 2-8, D-72076 Tübingen, Germany, e-mail: [drmed\\_lukas@web.de](mailto:drmed_lukas@web.de), <http://www.periotest.de/lukas/>

\*\*\* Dentist, former Department of Oral Surgery and Periodontology, Dental School, University of Tübingen, Oslanderstr. 2-8, D-72076 Tübingen, Germany

\*\*\*\*Professor Emeritus, Department of Oral Surgery and Periodontology, Dental School, University of Tübingen; and Former Speaker of Special Research Project SFB175 "Implantology" (German Society of Research), Oslanderstr. 2-8, D-72076 Tübingen, Germany

**Reprint request:** Priv.-Doz. Dr. G. Gomez-Roman, Poliklinik für Zahnärztliche Prothetik und Propädeutik, Universitätsklinikum Tübingen, Oslanderstrasse 2-8, D-72076 Tübingen, Germany, Fax: +49-7071-293 982, e-mail: [german.gomez-roman@med.uni-tuebingen.de](mailto:german.gomez-roman@med.uni-tuebingen.de)

## Area-dependent enlargement ratios of panoramic tomography depending on asymmetric incorrect patient positioning and its significance for implant dentistry (Part 2)

### Abstract

**Objective:** This article investigates the behavior of the vertical and horizontal magnification factors on panoramic radiography images with asymmetrical incorrect patient positioning. The results for *optimum* positioning have been published in Part 1. The study using *symmetrical incorrect* patient positioning is forthcoming as Part 3.

**Method and materials:** Various degrees of incorrect positioning of a macerated skull were set with a sliding and tilting table on the skull retainer. **Results:** Incorrect positioning of the skull influenced the vertical and horizontal magnification factors to different degrees. The most marked effects on the magnification factors were observed during rotation around the cranio-caudal axis. This meant that the bone volume available for implant placement was overestimated in all regions of the jaw. The horizontal magnification factor was influenced significantly more by incorrect positioning than the vertical one. **Conclusion:** When these results are considered, the panoramic radiography technique is shown to be a suitable procedure for both pre-implant diagnostics and also for monitoring the procedure and the success of the procedure. However, the results for symmetrical incorrect positioning are also required for further conclusions.

**Key words:** area-dependent; imaging technique with incorrect positioning; Frialit-2; enlargement, dental implantology; panoramic radiography; radiographic measuring

### Introduction

The significance of panoramic radiography for pre-implant diagnostics has been described in detail for orthograde positioning in the first section of this article<sup>1</sup> (with 24 literature citations). This part and the forthcoming [third part](#) deal with the magnification and distortion caused by incorrect patient positioning.

The correct position of the head as an important prerequisite for a metric evaluation is also described by Schopf<sup>2</sup>. If the patient is not correctly positioned, it becomes more difficult to compare two x-ray exposures of the same patient taken at different times. Assessment of the peri-implant situation is more difficult with inexact patient repositioning between the various control imaging sessions while monitoring an implant patient. For orthodontic examinations Schopf<sup>2</sup> (62) studied the axial position of the teeth imposed in the panoramic radiography images. His results showed that the tooth axis angles are distorted primarily in the front tooth region and in part also in the premolar region, while measured values of molars could be used for diagnosis even with moderate deviation of the head setting.

Ramstad et al.<sup>3</sup> (57) investigated the dimensions of various error sources on the magnification factors with measurements of the height of the alveolar ridge of edentulous patients. Significant variations in measurements were obtained here, derived from repeated images of the same patients and during the interaction among dentist, patient and x-ray apparatus. This result emphasizes the requirement for assistance in achieving the exact patient positioning, such as suitable supporting elements.

The useful information in exposures resulting from asymmetrical images taken while the patient is incorrectly positioned is rarely addressed in the literature. The question of whether different incorrect positions influence the vertical and horizontal magnification factors in the various regions to a degree significant for implant dentistry is examined below. x-ray images taken during symmetrical incorrect positioning are discussed in the forthcoming third part.

## **Material and Methods**

The examinations were conducted on an average-shaped, edentulous, macerated skull of unknown sex, age and race. The skull contained 26 Frialit™-2 stepped cylinder implants 11 mm in length and 3.8 mm in diameter. The full procedure including the x-ray technique in the optimum orthograde setting has been described in detail in the first part of this study<sup>1</sup>.

The macerated skull was fixed on a plane or axis that deviated from its optimum orthograde position and x-rayed to examine the influence to the incorrect positioning on the distortion and magnification factors. The following incorrect, asymmetrical settings with reference to the median sagittal plane were selected (compare the schematic views in the diagrams at top left):

**Sliding to the left relative to the transverse space plane:**

The skull was slid 2 mm, 3 mm, 4 mm and 6 mm to the left along a milled slot on its steel base after the optimum orthograde position had been set. The slot ran exactly parallel to the transverse plane of the skull and so was aligned symmetrically to the x-ray unit loop.

**Tilting to the left relative to the dorso-ventral space axis:**

The tilt was 1.5, 3, 4.5 and 6° at the ball and socket joint of the base. The milled mark in the steel plate was also parallel to the transverse plane of the skull. In contrast to the anatomical relationships the distance between the base joint and the occipital condyle of the skull was significantly too large at 30 cm, while in the physiological sense the skull was tilted around the dorso-ventral body axis at the atlas. Therefore, after this and the following rotations, the skull was slid to the right along the slot in the steel plate to the point that relationships corresponding to the anatomical movement were almost reached. The dimension of the displacement was calculated with the following equation:  $x = r * \tan \alpha$ , where  $x$  is the displacement distance,  $r$  is the distance between the ball-and-socket joint of the base and the occipital condyle, and  $\alpha$  is the various tilt angles. After this repositioning the height setting of the x-ray apparatus was corrected to ensure optimum positioning of the macerated skull.

**Rotation to the left around the cranio-caudal axis:**

The rotation was also set to 1.5, 3, 4.5 and 6° at the ball-and-socket joint of the base. With this incorrect position the milled line on the steel plate was again aligned along the transverse plane of the skull. The skull could be fixed exactly perpendicular above the ball-and-socket joint but was anchored slightly in front of the center of rotation. As compensation the skull was also moved to the right along the milled slot as above and finally the height of the x-ray unit was corrected.

In total three different classes of asymmetrical incorrect positions were examined and each class was classified into four subclasses according to the degree of incorrect adjustment. Six panoramic radiography images were made of every subclass.

Cephalometric analysis, measurement of the implants and the statistical methods used were described in detail in the first part of this study <sup>1</sup>.

## Results

The magnification factors of the incorrectly positioned panoramic radiography images were based on the results with orthograde position and placed relative to the reproducibility of the settings of the x-ray apparatus (see Part 1 "Statistical Methods" and "Reproducibility of the Settings on the x-ray Apparatus" <sup>1</sup>). All magnification factors with incorrect positioning were calculated from six individual values for every one of the four degrees, and with orthograde positioning from 18 individual values.

**Sliding to the left in the transverse plane.** The changes of the *vertical* magnification are shown in [Fig. 1](#). In the case of this incorrect positioning the vertical magnification factors in the right halves of the jaws increased with the degree of incorrect positioning, but in contrast they decreased in the left halves of the jaws. However, these changes exceed the dimension of the reproducibility of the settings at the x-ray apparatus in part only (vertical error bar).

With the *horizontal* magnification at the coronal implant step, a significantly more marked influence by sliding the head was clear in comparison to the vertical magnification factors ([Fig. 2](#)), just as with the other incorrect positioning. On the right the magnification exceeded that of the orthograde positioning, but on the left the magnification factors were smaller. This change is significant with reference to the reproducibility of the settings on the x-ray apparatus. In the right half of the jaw the magnification factors increased with the degree of incorrect positioning while in the left half they decreased.

**Tilt to the left around the dorso-ventral axis.** The dependence of the *vertical* magnification factor on the degree of tilt and the dental region is shown in [Fig. 3](#). With this incorrect positioning a reduction of the vertical magnification factor could be observed in the first and fourth quadrants with increased tilting of the skull, while it increased in the second and third quadrants. With reference to the reproducibility the magnification factors in the right half of the maxilla were lower compared to orthograde positioning only in the region of the incisors, premolars and at the tuber. In the right half of the mandible the magnification factor is reduced only in the molar and premolar regions. In the second quadrant a significantly increased magnification was visible only in the third molar, but this was evident in all regions in the third quadrant with a tilt of  $6.0^\circ$  and from  $4.5^\circ$  in the lateral dental region.

The changes in the *horizontal* coronal magnification are shown in [Fig. 4](#). The horizontal magnification factor was reduced in the first and fourth quadrants with increasing incorrect positioning. In contrast, the magnification in the second and third quadrants increased with the degree of incorrect positioning. The changes were mostly significant.

**Rotation to the left around the cranio-caudal axis.** The changes of the *vertical* magnification factor are shown in [Fig. 5](#). The magnification increased in all regions of the right quadrants with the increase of the angle of rotation, while in the left quadrants it fell. These changes exceeded the dimension of reproducibility in all regions and in part at rotations of  $1.5^\circ$  and  $3^\circ$ .

The *horizontal* magnification was influenced by even small angles of rotation, as shown in [Fig. 6](#). The right maxillary and mandibular halves were shown larger on incorrect positioned panoramic radiography images, while in the left halves of the jaws they were shown reduced. In the third quadrant the magnified view of the object typical for panoramic imaging tended not to be magnified (0.99).

## Discussion

The study by McIver et al. <sup>4</sup> classified the incorrect positioning similarly to that used in our study, but did not use different degrees of severity. A direct comparison is difficult, because the study was conducted on a juvenile skull with a dental age of five years and with a panoramic x-ray apparatus from a different company (Panorex x-ray apparatus).

Evaluation of our results with the images in the *transverse plane slid to the left* has demonstrated that the implants of the right halves of the jaw were magnified more strongly in the horizontal direction than in the vertical. These implants were repositioned from the sharply imaged slice in the direction of the center of rotation, increasing its distance to the film. In contrast to the above, the magnification factors of the implants of the left region of the jaw, which shifted simultaneously in the direction of the film, decreased more strongly in the horizontal direction than in the vertical. This matches the observations made by Zach et al. <sup>5</sup> and Tronje et al. <sup>6</sup>. In the anterior region of the right half of the maxilla, a wider implant image in the horizontal direction must be expected, while a narrowed implant image must be expected in the left half of the maxilla and mandible. This incorrect positioning correspondingly results in a magnification of the bone structures in the region of the right half of the jaw and a reduction of the left half of the jaw. This depends on the degree of sliding. With panoramic radiography images without reference structures of known dimensions this can result in overestimating the right side of the bone volume available for implant placement and underestimating that available on the left side in the vertical and horizontal dimensions.

The tilt around the *dorso-ventral axis* is an incorrect positioning that is difficult to exclude, particularly in the case of edentulous patients. This is because the patient is positioned in the x-ray apparatus with a subnasal support only and secure fixing over the occlusion is possible only to a limited extent. The results of the study for a tilt to the *left* showed that the implants in the right half of the jaw are reduced in the vertical and enlarged in the horizontal dimension in comparison with the orthograde setting, while in the left half of the jaw they are enlarged. Apart from the change in the distance between the film and the object, the influence of

which was discussed above, the changed oro-vestibular tilt of the implants and the change of the object depth – thus to another position between the x-ray source and the film – are important for the magnification because of the change in the position of the head. The greatest change in the vertical magnification factor compared to the orthograde image at maximum incorrect positioning occurred in the wisdom tooth region, because the angulation angle and the inclination angle is steepest in this region. This means a shortened implant view in the right wisdom tooth regions compared to an orthograde positioned panoramic image and an elongated image in the left wisdom tooth regions.

In the horizontal dimension an implant in the right premolar tooth region was shown narrowed and one in the left premolar tooth region was shown widened. Without additional structures to assist in determining the magnification factor this would result in underestimating the bone volume of the right half of the jaw and overestimating that of the left half of the jaw.

When the vertical and horizontal magnification factors are compared relative to the *rotation around the cranio-caudal axis to the left*, it is clear that the horizontal magnification, which tends to correspond to the vertical, reaches much more extreme values. This results in serious distortion of the implants in the panoramic images. The image with incorrect positioning is extended compared to orthograde settings, in this skull particularly in the premolar and molar regions of the right half of the jaw, and shortened in the left premolar region. This corresponds to an overestimation of the available bone volume on the right and an underestimation on the left.

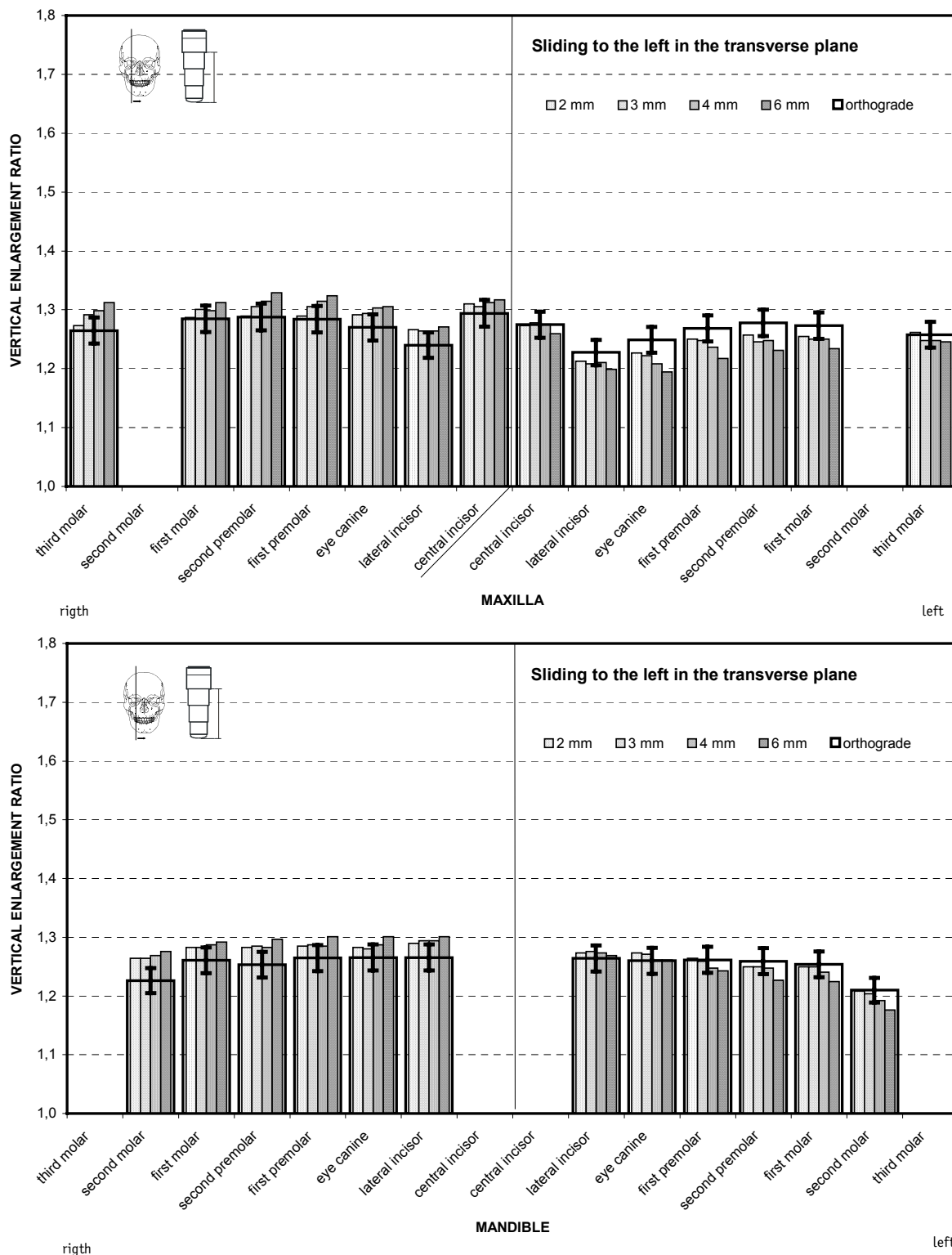
The results with symmetrical incorrect patient positions are required for further discussion. They are presented in the forthcoming [third part](#) of our study.

#### References

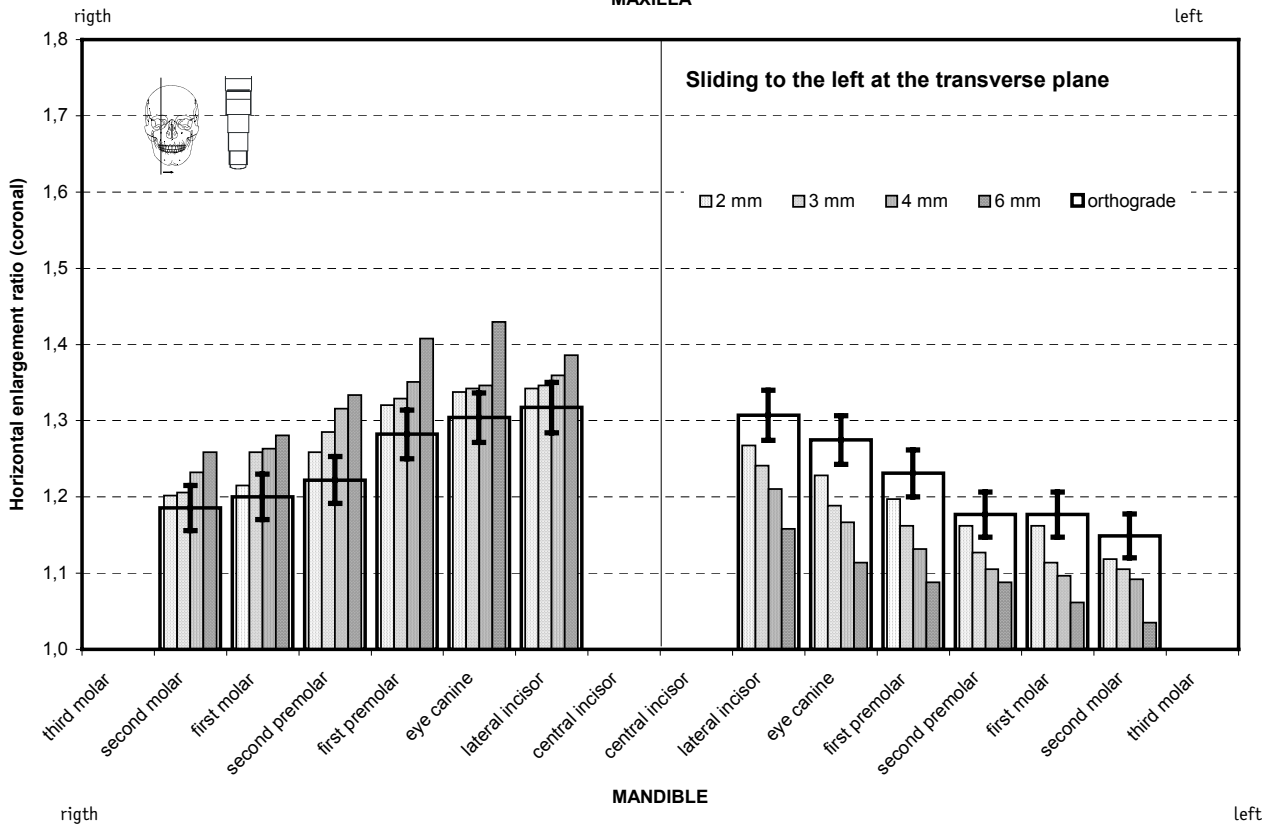
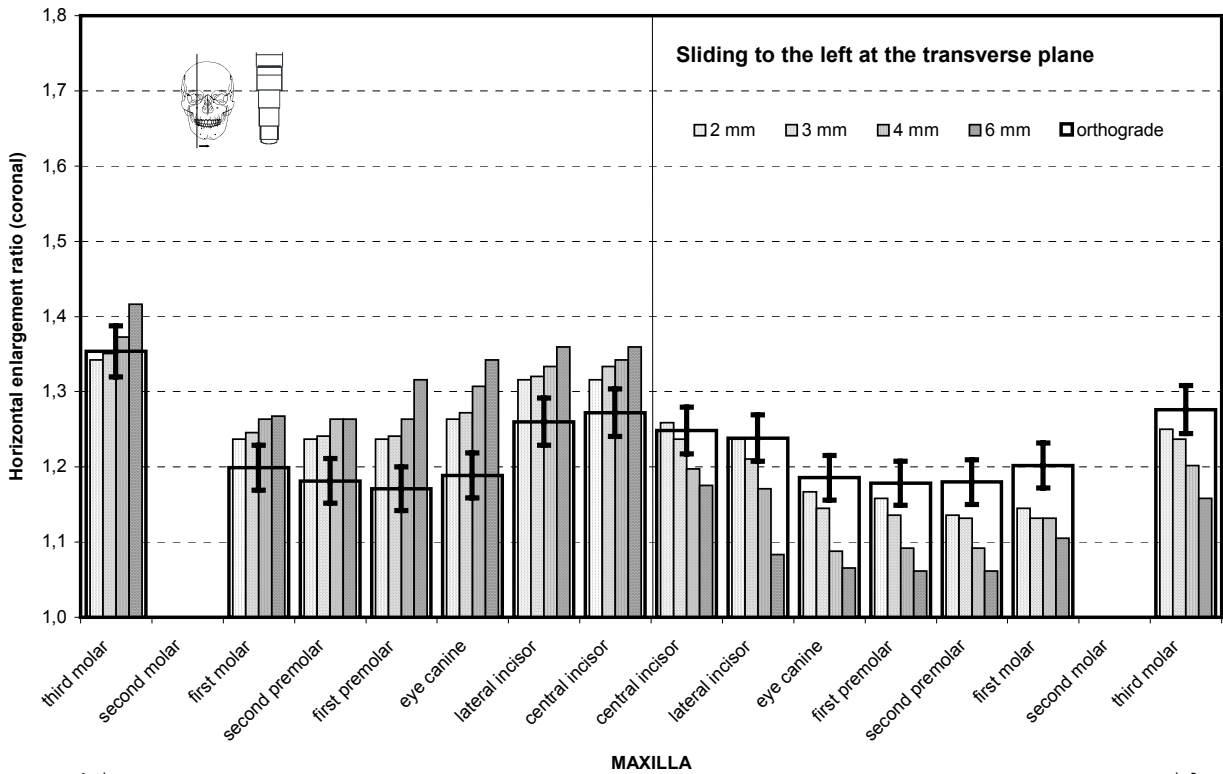
1. Gómez-Román G, Lukas D, Beniashirili R, Schulte W. Area-dependent Enlargement Ratios of Panoramic Tomography on Orthograde Patient Positioning and Its Significance for Implant Dentistry. *Int J Oral Maxillofac Implants*, 1999; 14: 248-257.



2. Schopf P. Längen und Winkelmessungen am Orthopantomogramm. Fortschr Kieferorthop, 1966; 27: 107-114.
3. Ramstad T, Hensten-Pettersen O, Mohn E, Ibrahim SI. A methodological study of errors in vertical measurements of edentulous ridge height on orthopantomographic radiographs. J Oral Rehabil, 1978; 5: 403-412.
4. McIver FT, Hill C, Brogan DR, Lyman GE. Effect of head positioning upon the width of mandibular tooth images on panoramic radiographs. Oral Surg Oral Med Oral Pathol, 1973; 35: 697-707.
5. Zach GA, Langland OE, Sippy FH. The use of the Orthopantomograph in Longitudinal Studies. Angle Orthod, 1969; 39, No.1: 42-49.
6. Tronje G, Eliasson S, Julin P, Welander U. Image distortion in rotational panoramic radiography. II. Vertical distances. Acta Radiol Diagn Stockh, 1981; 22: 449-455.



**Fig 1** Average vertical magnification in the maxilla (top) and the mandible (bottom) during *sliding to the left in the transverse plane*. The narrow, increasingly filled pillars show the results with a incorrect position, with increasing degree to the right. The magnification factors with an orthograde setting are shown by the superimposed wide rectangle, and the reproducibility of the settings at the x-ray apparatus (3.5%) as vertical lines.



**Fig 2** Average horizontal magnification at the coronal end of the implant during *sliding to the left at the transverse plane*. The view corresponds to Fig. 1, the reproducibility of the settings at the x-ray apparatus is 5%.

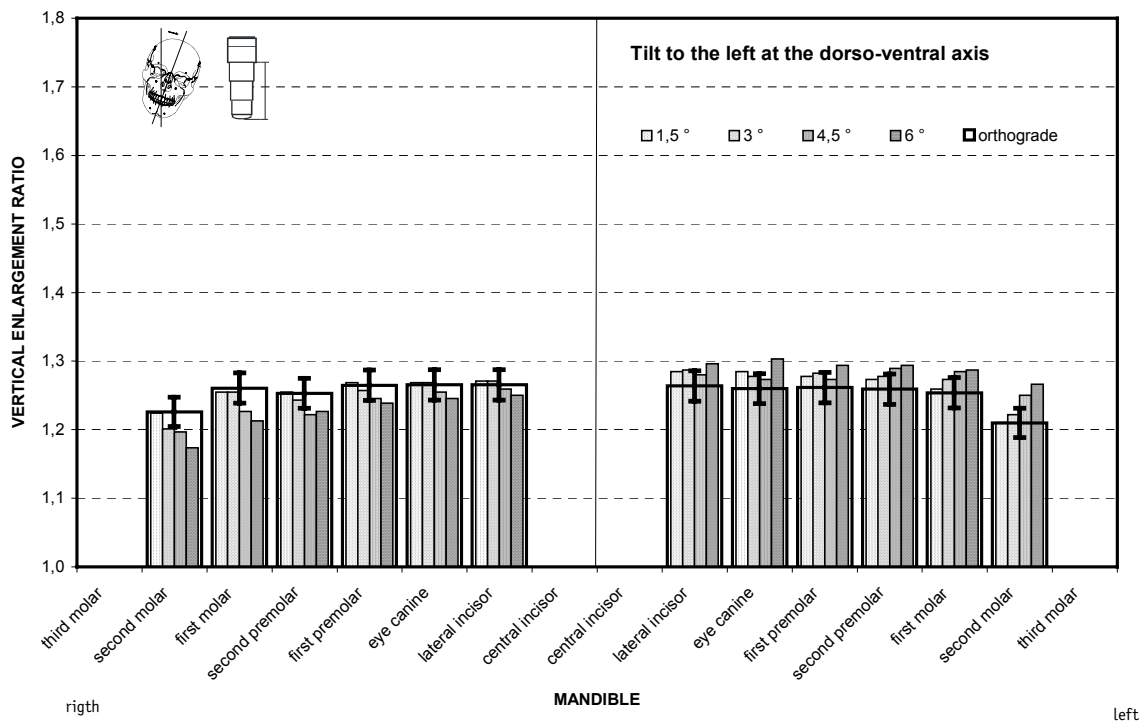
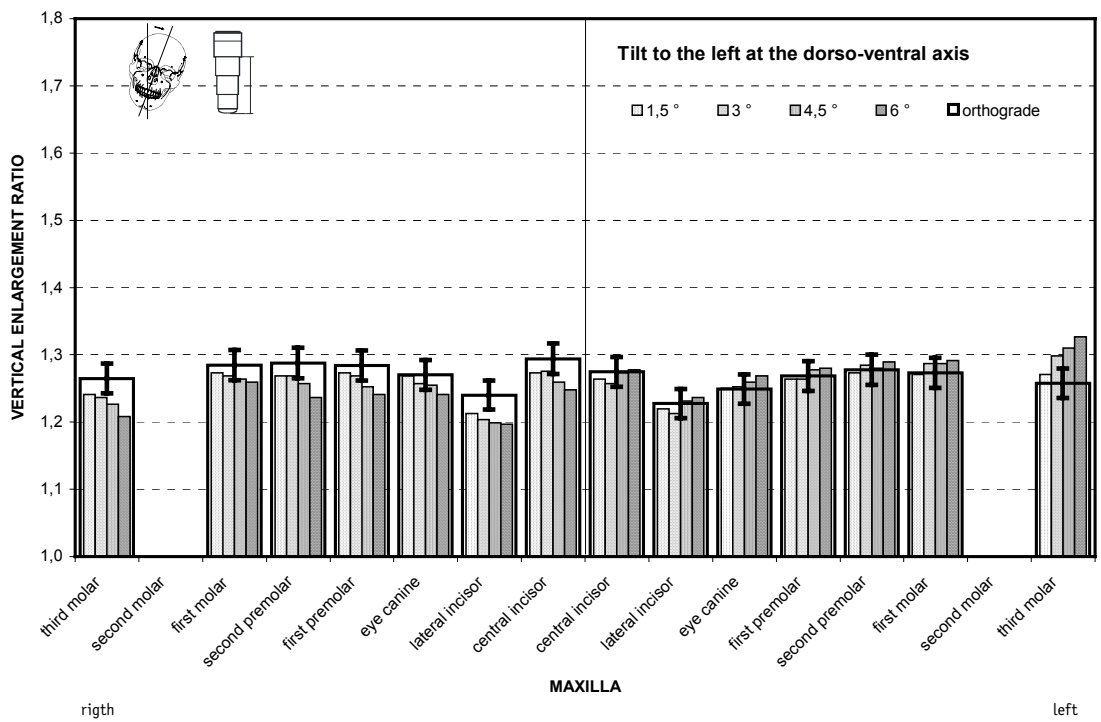
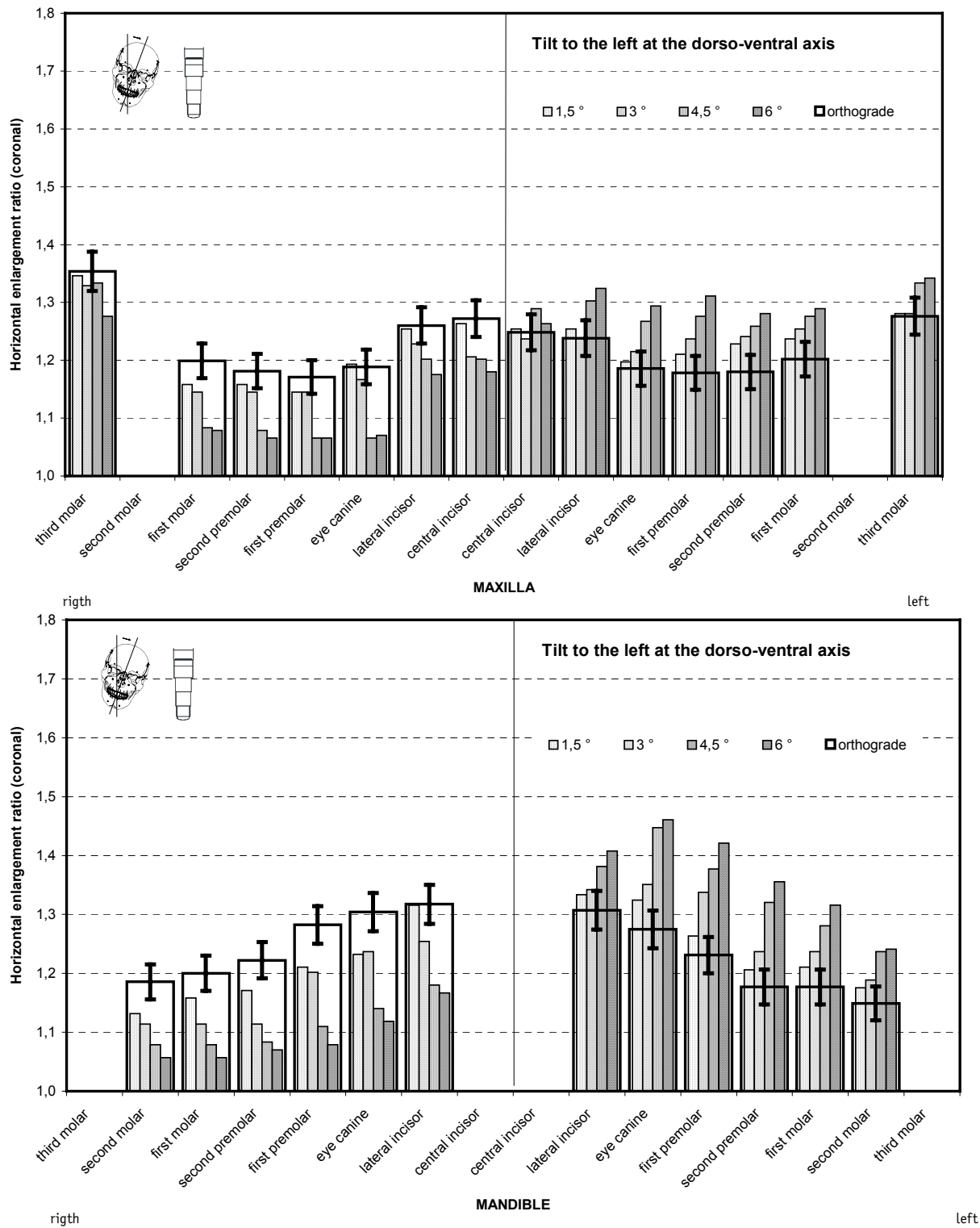


Fig 3 Average vertical magnification with *tilt to the left at the dorso-ventral axis*. The narrow, increasingly filled pillars show the results with a incorrect position, with increasing degree to the right. The magnification factors with an orthograde setting are shown by the superimposed wide rectangle, and the reproducibility of the settings at the x-ray apparatus (3.5%) as vertical lines.



**Fig 4** Average horizontal magnification at the coronal end of the implant with *tilt to the left at the dorso-ventral axis*. The view corresponds to Fig. 3. The reproducibility of the settings at the x-ray apparatus is 5%.

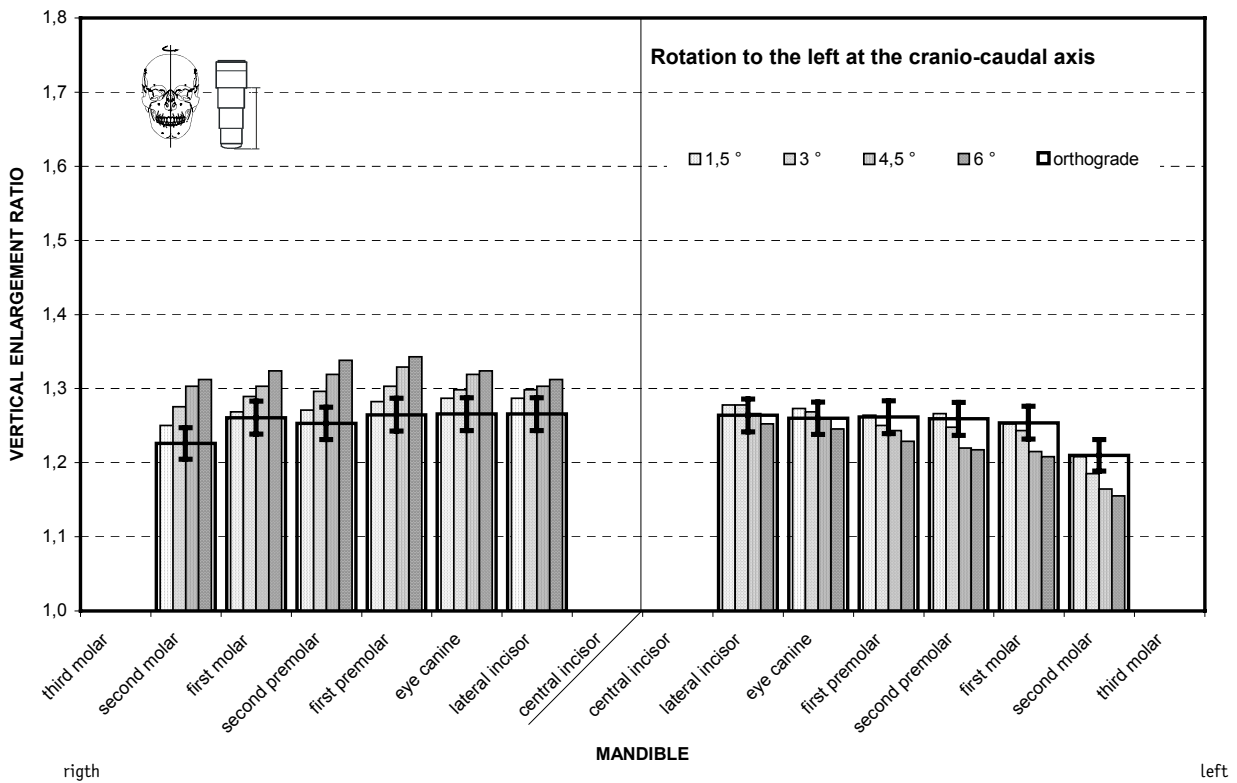
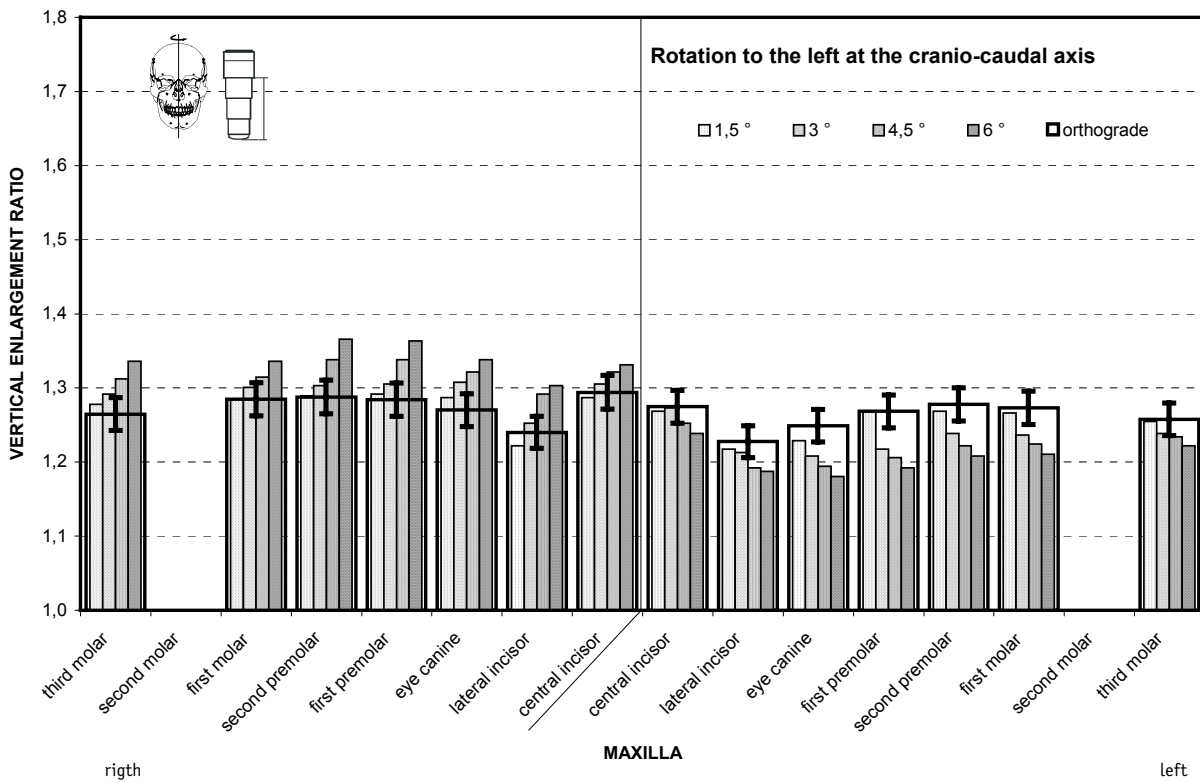
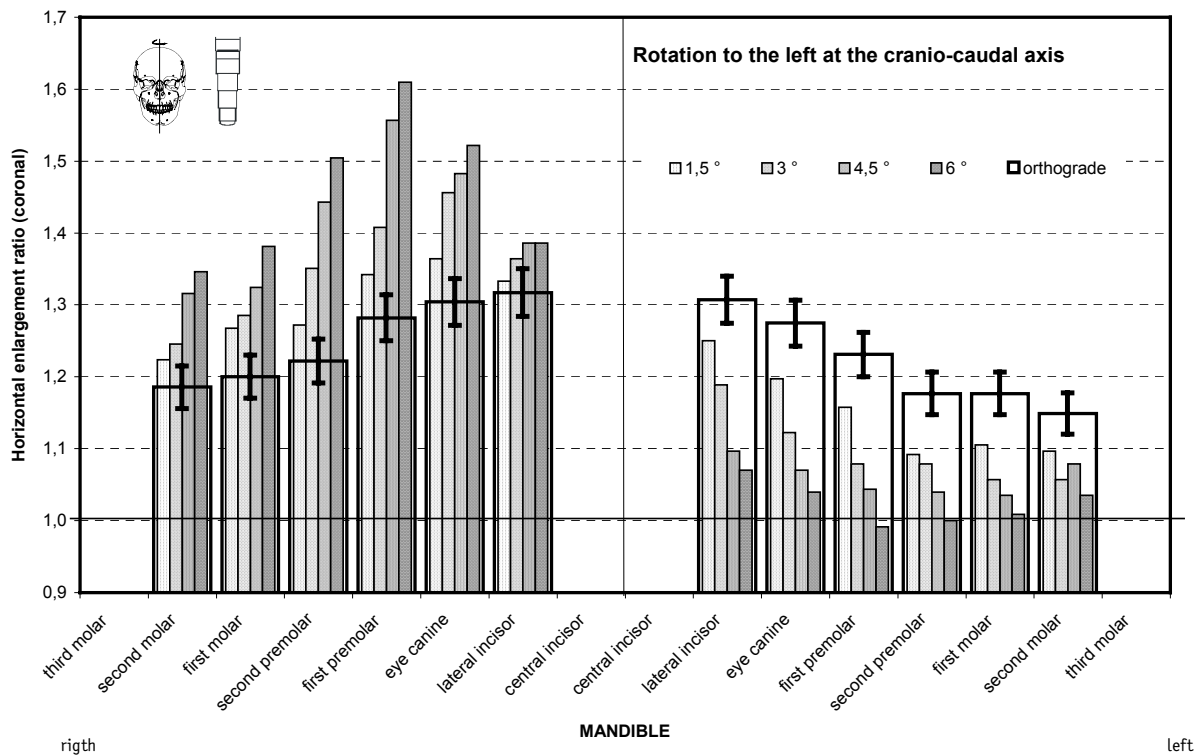
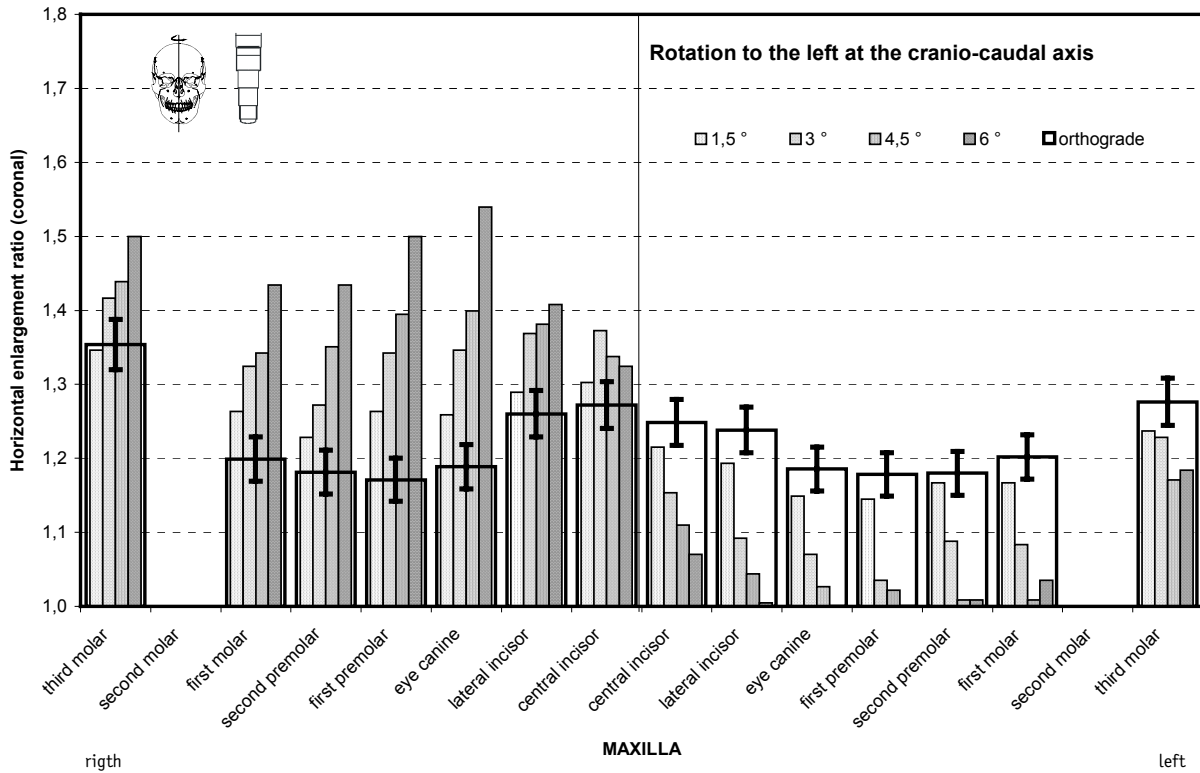


Fig 5 Average vertical magnification with *rotation to the left at the cranio-caudal axis*. The narrow, increasingly filled pillars show the results with a incorrect position, with increasing degree to the right. The magnification factors with an orthograde setting are shown by the superimposed wide rectangle, and the reproducibility of the settings at the x-ray apparatus (3.5%) as vertical lines.



**Fig 6** Average horizontal magnification at the coronal end of the implant with *rotation to the left at the cranio-caudal axis*. The view corresponds to Fig. 5, the reproducibility of the settings at the x-ray apparatus is 5%. In part the magnification characteristic with panoramic radiography images reverses to become a reduction (note the 1.0 line).