

NEW MORPHOMETRIC METHODS IN PALEOPATHOLOGY: SHAPE ANALYSIS OF A NEOLITHIC HYDROCEPHALUS

ABSTRACT

P. MITTEROECKER

VIENNA INST. FOR ANTHROPOLOGY, VIENNA, AUSTRIA

P. GUNZ

VIENNA INST. FOR ANTHROPOLOGY, VIENNA, AUSTRIA

M. TESCHLER-NICOLA

MUSEUM OF NATURAL HISTORY VIENNA, AUSTRIA

GW. WEBER

VIENNA INST. FOR ANTHROPOLOGY, VIENNA, AUSTRIA

We provide a shape analysis of a Middle Neolithic (4900-4300 BC) human cranium introducing a new tool to geometric morphometrics: semilandmarks on surfaces.

Two hydrocephalics (34 and 12 years old) and a control group of morphologically regular formed crania (N=20) ranging from 2 years of age to adults are compared against an adolescent middle Neolithic specimen which is presumably hydrocephalic.

42 anatomical landmarks and several thousand points on the neurocranial surface were either digitised using a Polhemus device or extracted from CT-data. Our algorithm automatically places 336 semilandmarks on the neurocranium and relaxes them against the Procrustes average preserving just information perpendicular to the surface. These three dimensional semilandmarks offer the opportunity of incorporating information about curved forms that lack traditional landmarks into statistical shape analysis.

While all 3 hydrocephalics possess very prominent parietal bosses, the Neolithic hydrocephalus is different in frontal bone shape, lying close to the variability obtained in the control group. This suggests that the Neolithic specimen could represent a case of acquired hydrocephalus where the sutures at the parietal and occipital region of the skull still had enough degrees of freedom to compensate the intracranial pressure, whereas the frontal suture had already fused.

INTRODUCTION

Hydrocephalics from prehistoric time are rare findings (Teschler-Nicola et al. 1986, Schultz and Teschler-Nicola 1989) and - in addition - questions concerning differential diagnosis and causality are often hampered by their poor preservation status and fragmentary character (Teschler-Nicola and Gerold, in press). A completely preserved skull of a subadult individual excavated in Kamegg, Lower Austria and dated to the middle Neolithic is assumed to be hydrocephalic (Teschler-Nicola et al. 1986): Not only the enlarged neurocranium but also the results of a detailed analysis of patho-

morphological features predominantly manifested at the internal cranial base gave arguments to support this hypothesis. Nevertheless, the Kamegg skull is distinct to most other known hydrocephalics, since it exhibits a moderately large and triangular shaped cranial vault (Fig.1a-c) whereas the "classical" hydrocephalics possesses a typical large rectangular shaped neurocranium (Fig.1d). According to histological and detailed investigations of pathological features an inflammation in the region of the right temporal bone (Otitis media), or a trauma of the cranial vault during early childhood could be responsible for the characteristic features in this case of a probably acquired hydrocephalus.

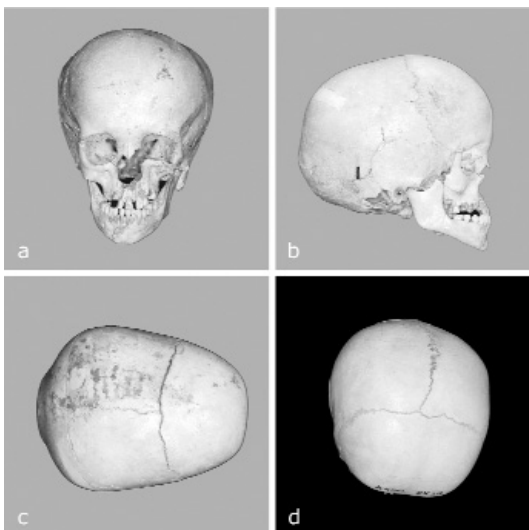


Figure 1 Photographs of the Neolithic specimen (a, b, c) and the 32 year old hydrocephalic (d)

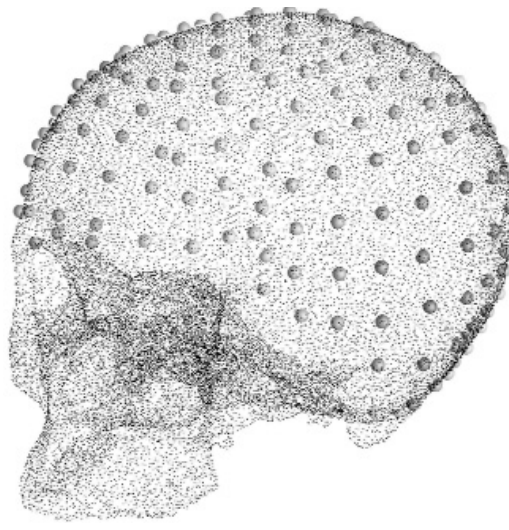


Figure 2 Dense surface points extracted from a CT-scan and semilandmarks on the neurocranial surface (larger spheres)

The use of traditional metric analysis for differential diagnostic purpose lacks reliability since they do not include landmarks of the most diagnostic regions on the skull, e.g. the cranial bosses. We therefore applied a rather new morphometric method, semilandmarks on surfaces (Mitteroecker et al., in press), to compare the Neolithic skull - which is representing the most ancient

hydrocephalic finding in Europe - to a set of anamnesticly well documented pathologic specimens as well as a set of inconspicuous modern reference skulls for the improvement of the hypothesis of representing an acquired pathology.

MATERIAL

During the systematic archaeological investigation in the middle-Neolithic concentric ditch system in Kamegg, Lower Austria, carried through by the Institut für Ur- und Frühgeschichte, University of Vienna in 1984 (Trnka 1986), a well preserved skeleton of an immature individual was found at the base of a settlement pit. Based on fragmentary pottery the finding can be attributed to the Lengyel-culture, 4900-4300 BC. By using dental eruption and mineralisation the age of death of the individual was restricted to 10 - 12 years. Regarding this subadult age, non-conventional methods such as dental dimensions and relative proportions of tubular skeletal elements have been used to determine the individual's sex: The majority of the metric dimensions of that features are in favour of a female.

The most conspicuous morphological feature in this individual is the enlargement of the neurocranium in length and width and an 40% extension of the cranial capacity compared to the reference skulls. Impressive and characteristic is the triangular shape of the Neolithic specimen in the vertical (and the trapezoidal shape in the occipital) view, which is resulting from the considerable development of the parietal bosses.

For a comparative morphometric analysis we used two recent hydrocephalic skulls (age at death: 34 and 12 years) and a control group of morphologically regular formed crania (N=20, age of death: 2 years to adult).

The two hydrocephalics belong to the collection of the Federal Pathologic-Anatomical Museum Vienna (diagnosis were made by former pathologists and recorded in ancient hand written inventories), all other specimens are part of the osteological collections housed at the Department of Anatomy, University of Vienna and the Department of Anthropology, Natural History Museum Vienna.

METHODS

We digitized 42 clearly identifiable anatomical landmarks on the whole skull and several thousand random points on the neurocranial surface either using a Polhemus device or a CT-reconstruction of the specimens. Based on this surface scatter our algorithm automatically places 336 semilandmarks on the neurocranium and relaxes them against the Procrustes average to decrease bending energy between them (Fig.2). This algorithm omits information about shape deformation along the surface (that is an artefact of landmark spacing) while preserving information perpendicular to the surface (that is due to morphological differences). The resulting semilandmark positions can thus be treated as homologous in the subsequent sta-

tistical analyses (Bookstein 1997, Mitteroecker et al., in press). The 23 sets of 378 landmarks were superimposed using a GLS Procrustes registration (Rohlf and Slice 1990) which partials out position, size, and orientation. The resulting Procrustes coordinates contain shape information only and overall size is measured explicitly as centroid size (the square root of the sum of squared distances from all landmarks to their centroid). For the explorative study of shape we use relative warps analysis (i.e. principal components of Procrustes coordinates, see Bookstein 1991, Rohlf 1993).

RESULTS

Centroid size as a measurement for overall scale for each individual is plotted in Figure 3. While the Neolithic specimen is larger than all skulls of the control group, it is also clearly smaller than the two hydrocephalic skulls. In a relative warps plot of all neurocranial landmarks the hydrocephalics and the Neolithic specimen are completely separated from the control sample (Fig.4a). When only the semilandmarks on the frontal bone are analyzed (b), the Neolithic specimen does not cluster together with the other hydrocephalics though it is distinct from the reference population. With respect to the first Relative Warp its shape is completely different from the other two pathologic cases. If only the posterior part of the cranium was analyzed, the two hydrocephalics and the Neolithic specimen are clearly separated from the control group but cluster together (not shown). Even when the specimen's size is considered in the analysis by re-multiplying the shape coordinates by their respective centroid size before performing the relative warp analysis (c, d), the frontal bone of the adolescent Neolithic specimen lies very close to the normal variation.

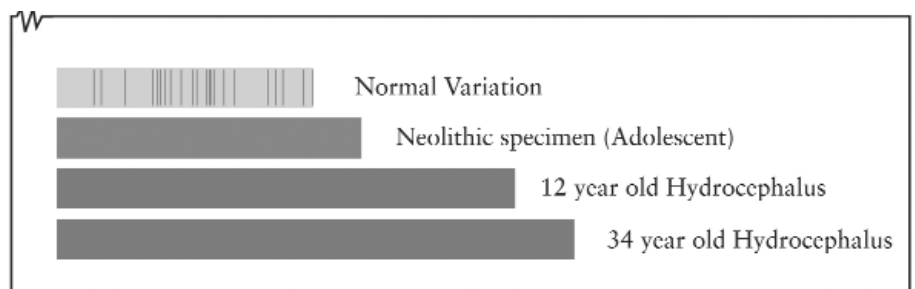


Figure 3 Centroid size as a measure of overall scale. The upper bar shows the size range of the control sample, the black lines marking single specimens. The adolescent Neolithic cranium is larger than all non-pathological cases

Figure 4 shows the actual differences of the neurocranial shape of the hydrocephalics to the mean form of the control sample. Both known hydrocephalics exhibit enlarged frontal and parietal bosses (a, b) while the Neolithic specimen's neurocranium, though generally enlarged, mainly deviates in its posterior regions.

DISCUSSION

The shape analysis confirms the impression that in the Neolithic specimen almost only the parietal bosses seem to be enlarged while the form of the frontal bone lies close to the normal adult variation (Fig. 4). Richards and Anton (1991)

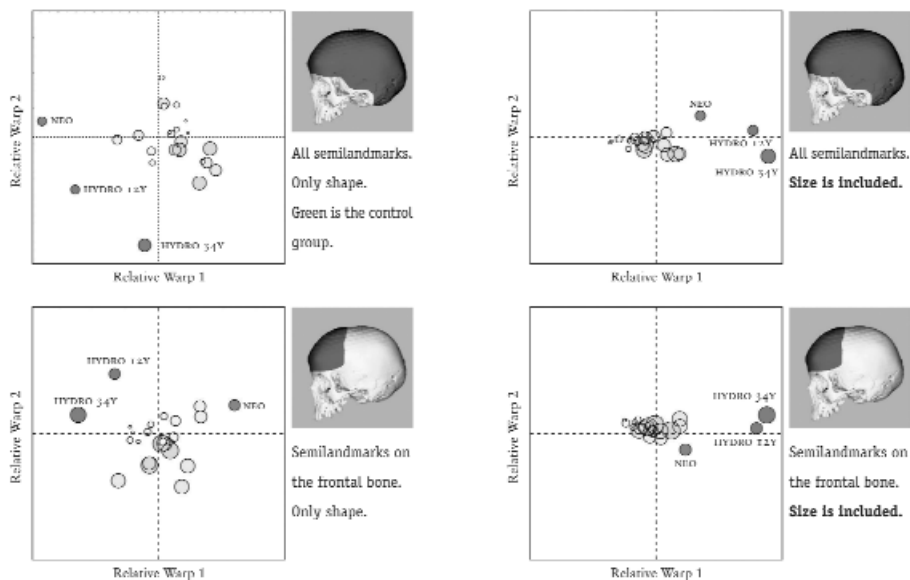


Figure 4 Relative warp analysis (principal components of Procrustes coordinates). Age is coded by disk size; the control group is unlabeled. The hydrocephalics and the Neolithic specimen are separated from the control group. When only the semi-landmarks on the frontal bone are analyzed, the Neolithic specimen does not cluster together with the other hydrocephalics but is still distinguishable from the control group. This keeps true also when the specimen's size is considered in the analysis by re-multiplying the shape coordinates by their respective centroid size

distinguish between rectangular and more triangular shaped hydrocephalics and suspect the reason therefore in a communicating versus non-communicating form of hydrocephaly. We add another explanation: The different onset of the cause for the enlargement. If the intracranial pressure rises because of an increase of cerebrospinal fluid (CSF), the hydrostatic pressure against the skull vault is likely to be more or less uniformly distributed over the whole interior cranium. The head does not expand isometrically, though; the bones can compensate the pressure only in certain areas, depending mainly on the cranial sutures. In congenital (or very early acquired) hydrocephalus, none of the sutures have fused-the intra-cranial pressure causes the head to expand rather uniformly resulting in a rectangular shape. When hydrocephaly is acquired later in life, the frontal suture is already fused and the cranium can only expand in the parietal and occipital region, leading to a triangular shape.

morphometric analysis because they are well defined in just one dimension and lack the other two coordinates. In this study we have approached this problem by applying semi-landmarks on surfaces (Mitteroecker et al., in press). With this method we could show differences in neurocranial form and shape between the Neolithic specimen and the control group as well as the two hydrocephalic skulls.

In the current example it would be hard to diagnose hydrocephaly on the frontal bone only, but we clearly could distinguish the Neolithic individual from the others in the relative warp plots (Fig.3b, d). The methods shown in this study can provide a quantitative and transparent way in the identification of anomalous morphologies.

ACKNOWLEDGEMENTS

We thank F. Bookstein, J. Kim, B. Patzak, H. Prossinger, K. Schaefer, H. Seidler, D. Slice and T.B. Viola for access to material and helpful discussions. This study was supported by the Austrian Science Foundation P14738.

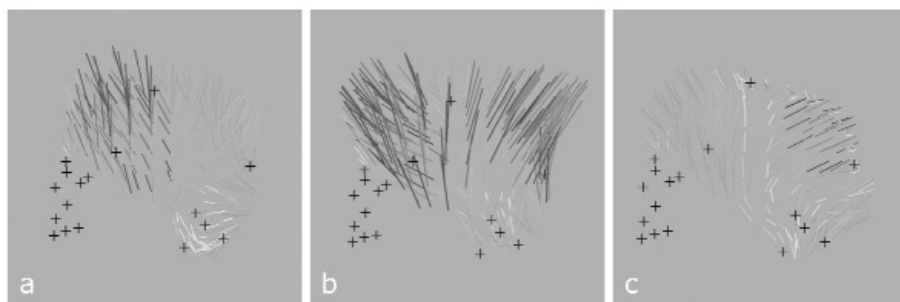


Figure 5 Shape residuals of the semilandmarks after the real landmarks (black crosses) were warped to the consensus. The little lines visualize direction and magnitude (length and color) of deviation from the mean form of the control sample. The two hydrocephalics (a, b) are easy to recognize because of their enlarged frontal and parietal bosses. The Neolithic cranium (c) shows some differences compared to the other two hydrocephalics - the parietal bosses are very enlarged while the frontal bosses exhibit only small expansion

The frontal suture normally fuses until the age of two, so the Neolithic skull could represent a case of acquired hydrocephalus with an onset of intracranial pressure later than two years of age. This hypothesis is supported by the fact that the skull's endocranial lamina exhibits vestiges of an inflammatory process presumably caused by meningitis or meningoencephalitis. The latter can lead to obstructions of CSF flow and/or resorption defects-causing a dynamic block and increasing CSF pressure (Teschler-Nicola et al. 1986).

Traditional craniometrics offers only very few reliable landmarks on the neurocranium while the face possesses a lot of unequivocally defined point locations (Type I and II, as defined by Bookstein 1991). Landmark definitions based on maximal extensions like Eurion (Type III landmarks) are not suited for geometric

REFERENCES

BOOKSTEIN, F., 1991. Morphometric tools for landmark data: geometry and biology. Cambridge University Press, Cambridge/New York.

BOOKSTEIN, F., 1997. Landmark methods for forms without landmarks: morphometrics of group differences in outline shape. *Med Image Anal* 1(3):225-43.

MITTEROECKER, P., GUNZ, P. et al., in press. Semilandmarks in three dimensions - Modern Methods in Anthropology. D.E. Slice, Kluwer.

RICHARDS, G.D. and ANTON, S.C., 1991. Craniofacial Configuration and Postcranial Development of a Hydrocephalic Child (ca. 2500 B.C. - 500 A.D.): With a Review of Cases and Comment on Diagnostic Criteria. *Am J Phys Anthropol* 85:185-200.

ROHLF, F.J. and SLICE, D.E., 1990. Extensions of the Procrustes method for the optimal superimposition of landmarks. *Syst. Zool.* 39:40-59.

ROHLF, F.J., 1993. Relative warp analysis and an example of its application to mosquito wings. Contributions to Morphometrics. In Marcus, L.F., Bello, E., and García-Valdecasas, A. (eds.), *Monografias*, Museo Nacional de Ciencias Naturales, Madrid:131-159.

SCHULTZ, M. and TESCHLER-NICOLA, M., 1989. Osteologische Untersuchungen an bronzzeitlichen Kinderskeletten aus Franzhausen, Niederösterreich. *Verh. Anat. Ges., Leipzig*:82, 407-409.

TESCHLER-NICOLA, M., SCHULTZ, M., KILLIAN, W. and LUBEC, G., 1986. Osteologische Untersuchungen an dem Kinderskelett aus der mittelpaläolithischen Kreisgrabenanlage von Kamegg, Niederösterreich. *Archeologia Austriaca* 70:113-136.

TESCHLER-NICOLA, M. and GEROLD, F., in press. Zur Paläoepidemiologie des mittelalterlichen Gräberfeldes von Gars/Thunau.

TRNKA, G., 1986. Vorläufige Ausgrabungsergebnisse der Kreisgrabenanlage von Kamegg (NÖ). *Archeologia Austriaca* 70:87-111.