

Aus der Universitätsklinik für Neurochirurgie Tübingen

**Endoscopic assisted surgery of posterior skull base
Analysis of the advantages**

**Inaugural-Dissertation
zur Erlangung des Doktorgrades
der Medizin**

**der Medizinischen Fakultät
der Eberhard Karls Universität
zu Tübingen**

**vorgelegt von
Mourad, Mohammed Ahmed Mahmoud Ahmed
2017**

Dekan: Professor Dr. I.B. Autenrieth

1-Berichterstatter: Professor Dr. M. Tatagiba

2-Berichterstatter: Privatdozentin Dr. M. Zdichavsky

Tag der Disputation: 15.03.2017

“What medicines do not heal, the lance will”

“First, do no harm”

Hippocrates (460BC–370BC)

“Every step of the procedure must be conducted under the eye of the operator.”

Harvey Cushing (1912)

Index

| | |
|---|-----------|
| INDEX..... | 4 |
| ABBREVIATIONS LIST..... | 7 |
| FIGURES LIST..... | 9 |
| TABLES LIST..... | 11 |
| 1. INTRODUCTION..... | 12 |
| 1.1. Background..... | 12 |
| 1.1.1. Minimally invasive skull base surgery..... | 12 |
| 1.1.2. History of the microscope in neurosurgery..... | 12 |
| 1.1.3. History of the endoscopic neurosurgery..... | 13 |
| 1.1.4. History of the endoscopic assisted surgery..... | 14 |
| 1.1.5. Endoscopic procedures..... | 14 |
| 1.2. Anatomy..... | 16 |
| 1.2.1. Anatomy of the posterior fossa..... | 16 |
| 1.2.2. Anatomy of the foramen magnum..... | 17 |
| 1.2.3. Anatomy of the CPA..... | 21 |
| 1.2.4. Anatomy of the fourth ventricle..... | 21 |
| 1.3. Pathology..... | 22 |
| 2. AIM OF THE WORK..... | 22 |
| 3. PATIENTS AND METHODS..... | 23 |
| 3.1. Retrospective data collection..... | 23 |
| 3.1.1. Patients data..... | 24 |
| 3.1.2. Pathology..... | 25 |
| 3.1.3. Preoperative management..... | 25 |
| 3.1.3.1 Clinical assessment..... | 25 |
| 3.1.3.2 Investigations..... | 26 |
| 3.1.4. Operative approaches..... | 26 |
| 3.1.5. Postoperative follow up and complications..... | 26 |
| 3.2. Surgical tools..... | 27 |
| 3.2.1. Essential tools..... | 27 |
| 3.2.2. Additional tools..... | 28 |

| | |
|---|-----------|
| 4. RESULTS..... | 29 |
| 4.1. Analysis of patients' data..... | 29 |
| 4.1.1. Patient characteristics..... | 29 |
| 4.1.1.1. Sex..... | 29 |
| 4.1.1.2. Age..... | 29 |
| 4.1.2. Pathology..... | 29 |
| 4.1.2.1. Previous surgery..... | 32 |
| 4.1.2.2. Location..... | 32 |
| 4.1.3. Clinical presentation..... | 33 |
| 4.2. Surgical approaches..... | 37 |
| 4.3. Outcome of endoscopic assisted surgery..... | 40 |
| 4.3.1. Tumor group..... | 41 |
| 4.3.1.1. Vestibular schwannoma..... | 41 |
| 4.3.1.2. Trigeminal schwannoma..... | 49 |
| 4.3.1.3. Epidermoid cyst..... | 49 |
| 4.3.1.4. Clival tumors..... | 53 |
| 4.3.1.5. Brain stem tumors..... | 54 |
| 4.3.1.6. Fourth ventricle tumors..... | 57 |
| 4.3.1.7. Foramen magnum tumors..... | 58 |
| 4.3.2. Non tumor group..... | 58 |
| 4.3.2.1. Vascular lesions..... | 58 |
| 4.3.2.2. CSF fistula repair..... | 60 |
| 4.3.2.3. Hemifacial spasm..... | 60 |
| 4.3.2.4. Trigeminal neuralgia..... | 60 |
| 4.4. Value of the endoscopic assisted procedure..... | 64 |
| 5. DISCUSSION..... | 64 |
| 5.1. Surgical procedures and techniques..... | 64 |
| 5.2. Outcome in various lesions..... | 66 |
| 5.2.1. CPA lesions..... | 66 |
| 5.2.2. Vestibular schwannoma..... | 67 |
| 5.2.3. Epidermoid CPA..... | 70 |
| 5.2.4. Clival tumors..... | 72 |

| | |
|--|------------|
| 5.2.5. Fourth ventricle tumors..... | 74 |
| 5.2.6. Foramen magnum tumors..... | 75 |
| 5.2.7. Trigeminal schwannoma..... | 76 |
| 5.2.8. Brainstem tumors..... | 78 |
| 5.2.9. Aneurysm of posterior circulation..... | 79 |
| 5.2.10. Trigeminal neuralgia..... | 81 |
| 5.2.11. Hemifacial spam..... | 84 |
| 5.3. The future of endoscopic-assisted technique..... | 86 |
| 6. CONCLUSION..... | 89 |
| REFERENCES LIST..... | 92 |
| ABSTRACT..... | 104 |
| ZUSAMMENFASSUNG..... | 106 |
| ACKNOWLEDGEMENT..... | 107 |
| CV..... | 109 |

Abbreviation List

| | |
|----------|-------------------------------------|
| 3D | Three-Dimensional |
| A | Artery |
| Ac | Acoustic |
| AEP | Auditory Evoked Potential |
| AICA | Anterior Inferior Cerebellar Artery |
| BA / Bas | Brainstem Auditory Evoked Potential |
| BAEP | Basilar Artery |
| CCD | Coupled Charged Device |
| Cer. Pon | Cerebellopontine |
| CN | Cranial Nerve |
| CPA | Cerebellopontine Angle |
| CSF | Cerebrospinal Fluid |
| CT | Computed Tomography |
| Dent | Dentate |
| DWI | Diffusion Weighted Image |
| EAM | Endoscopic Assisted Microsurgery |
| ECM | Endoscopic Controlled Microsurgery |
| EI | Endoscopic Inspection |
| EMG | Electromyography |
| EN | Pure Endoscopic Neurosurgery |
| Fiss | Fissure |
| For | Foramen |
| HB | House-Brackmann grading system |
| HFS | Hemifacial Spasm |
| HH | Hunt and Hess |
| IAC | Internal Auditory Canal |
| ICG | Indocyanine Green |
| ICU | Intensive Care Unit |
| Int | Internal |
| IOM | Intraoperative Monitoring |
| Jug | Jugular |

| | |
|----------|--------------------------------------|
| Labyr | Labyrinthine |
| LD | Lumbar Drainage |
| Lig | Ligament |
| Men | Meningeal |
| MEP | Motor Evoked Potential |
| MRI | Magnetic Resonance Imaging |
| MVD | Microvascular Decompression |
| Occip | Occipital |
| PCA | Posterior Cerebral Artery |
| Pet | Petrosal |
| PICA | Posterior Inferior Cerebellar Artery |
| Post | Posterior |
| Prox | Proximal |
| PTA | Pure Tone Audiometry |
| REZ | Root Exit Zone |
| SAH | Subarachnoid Hemorrhage |
| SCA | Superior Cerebellar Artery |
| SOL | Space Occupying Lesion |
| Sp | Spinal |
| SSEPs | Somato-Sensory Evoked Potentials |
| Suboccip | Suboccipital |
| Sup | Superior |
| Temp | Temporal |
| Tent | Tentorial |
| TOF | Time-of-Flight |
| V | Vein |
| VAS | Visual Analogue Scale |
| Vert | Vertebral |
| VS | Vestibular Schwannoma |

FIGURES AND DIAGRAMS LIST

| | |
|---|----|
| Fig. 1: History of the endoscope..... | 16 |
| Fig. 2: Anatomy of posterior fossa..... | 18 |
| Fig. 3: Anatomy of cerebellopontine angle (CPA)..... | 19 |
| Fig. 4: Vascular anatomy of the posterior cranial fossa..... | 20 |
| Fig. 5: Operation room set up, klinik für neurochirurgie UKT..... | 28 |
| Fig. 6: Groups of the patients..... | 30 |
| Fig. 7: Different pathologies of the tumor group..... | 31 |
| Fig. 8: Different pathologies of the non-tumor group..... | 31 |
| Fig. 9: Cases of recurrent pathology..... | 32 |
| Fig. 10: Side of the lesions..... | 33 |
| Fig. 11: VII affection in cases of VS and epidermoid cyst..... | 35 |
| Fig. 12: V affection in cases of VS and epidermoid cyst..... | 35 |
| Fig. 13: Different approaches for the posterior fossa..... | 37 |
| Fig. 14: Follow-up time in months..... | 41 |
| Fig. 15: Postoperative hearing follow-up in cases of VS..... | 42 |
| Fig. 16: VS according to Hannover`s Classification..... | 42 |
| Fig. 17: Management of opened mastoid air cells in endoscopic assisted technique..... | 43 |
| Fig. 18: Detection of rest tumor which not seen initially by the microscope | 44 |
| Fig. 19: Resection of rest tumor in EAM..... | 44 |
| Fig. 20: Microscopic view after removal of the tumor..... | 45 |
| Fig. 21: Detection of residual tumor after the microscopic removal of the tumor in another case..... | 45 |
| Fig. 22: Endoscopic view: Rest tumor resection..... | 46 |
| Fig. 23: Endoscopic view after the endoscopic-assisted removal of the tumor..... | 46 |
| Fig. 24: Preoperative images of left VS..... | 47 |
| Fig. 25: Postoperative images (immediate CT and follow up MRI)..... | 47 |

| | |
|--|----|
| Fig. 26: Immediate postoperative follow up in cases of VS..... | 48 |
| Fig. 27: Endoscopic view under microscopic control detecting rest of the tumor..... | 50 |
| Fig. 28: Preoperative images of epidermoid cyst..... | 51 |
| Fig. 29: Postoperative CT showing total removal of the tumor with intact BA..... | 51 |
| Fig. 30: Immediate postoperative follow up in cases of epidermoid cyst. | 52 |
| Fig. 31: Postoperative hearing follow-up in cases of epidermoid cyst..... | 53 |
| Fig. 32: Clival lesions..... | 54 |
| Fig. 33: Microscopic view: removal of the cavernoma..... | 55 |
| Fig. 34: Endoscopic inspection under microscopic control detecting no residual of the cavernoma..... | 55 |
| Fig. 35: Preoperative MRI, brain stem cavernoma..... | 56 |
| Fig. 36: Postoperative CT of brain stem cavernoma..... | 56 |
| Fig. 37: Vascular group..... | 59 |
| Fig. 38: Microscopic view: Loop of SCA compressing CN V..... | 61 |
| Fig. 39: Endoscopic view: Loop of SCA compressing CN V and exploration of the REZ..... | 62 |
| Fig. 40: Microscopic view: Teflon application..... | 62 |
| Fig. 41: Preoperative MRI of trigeminal neuralgia..... | 63 |
| Fig. 42: Postoperative CT of trigeminal neuralgia..... | 63 |

TABLE LIST

| | |
|---|----|
| Tab. 1: Presenting symptoms of each lesion..... | 34 |
| Tab. 2: Preoperative HB grade..... | 36 |
| Tab. 3: Postoperative HB grade..... | 36 |
| Tab. 4: Preoperative Hunt und Hess grade..... | 36 |
| Tab. 5: Postoperative hearing follow-up in cases of VS..... | 41 |

1. Introduction

1.1. Background

1.1.1. Minimally invasive skull base surgery

The primary concern of neurosurgery is focused on using minimally invasive techniques to allow less traumatic incision, less tissue injury, better wound healing, and better surgical outcome with minimal morbidity (Leek 1969).

Skull base surgery has been significantly progressed over the last decade because of the noticeable improvements in imaging, anesthetic, surgical techniques as well as the advancement of microsurgical instruments. However, the anatomical complexity of skull base makes dealing with lesions in such area a “surgical challenge.” That’s why looking for alternative methods rather than traditional surgery is needed. Recently, there have been significant advances in the field of skull base surgery with the help of endoscopic techniques to manage lesions in such area (Pirris et al. 2007).

1.1.2. History of the microscope in neurosurgery

The operating microscope is considered one of the most important tools in the modern era of surgery. It facilitates the success of the complex surgical procedures. Understanding principles of the vision and the optics over last decades was the keystone for the development of the microscope. In the 16th and 17th centuries, Lippershey, Janssen, Galileo, Hooke played a major role in the design of the early compound microscopes (Uluç et al. 2009).

In 1921, Carl Nylén, the father of the microsurgery initiated the revolution of microsurgery when he introduced the microscope into the operating room for the first time to treat a patient with otosclerotic deafness (Mudry 2000).

M. Gazi Yasargil, the father of the modern neurosurgery, was the first neurosurgeon who used the surgical microscope in the neurosurgical operation's room. He deserved to be the neurosurgery's man of the century. In 1953, Yasargil studied the neurovascular surgery with Prof. Hugo Krayenbühl in Switzerland. Dr. Pete Dinghy interested in his ideas and invited Yasargil to his microvascular laboratory in Burlington, Vermont (Tew 1999).

In 1957, Theodor Kurze used the operating microscope in a neurosurgical procedure at the University of Southern California, Los Angeles, to remove a facial nerve schwannoma from a 5-year-old child. The result of the surgery was excellent. He found a difficulty in sterilizing the microscope, but he solved this problem by using ethylene oxide gas (Kriss and Kriss 1998).

A lot of the refinements over the last 50 years improved the optical performance and handling of the microscope significantly. Today's compound microscopes give us the ability to get intraoperative angiographic imaging and sharp tumor identification (Uluç et al. 2009).

In the 1970s, Cushing's headlight and Dott's lighted speculum retractor had been replaced by the operating microscope as the lens provides better intraoperative imaging with superior magnification giving a chance for the modern concept of microsurgery to rise (Liu et al. 2001).

1.1.3. History of the endoscopic surgery

The word "Endoscopy" originates from two Greek words `endon` means inside and `scopein` ways to watch carefully (Fanous and Couldwell 2012).

The field of neuroendoscopy is full with a rich history of hardworking of pioneers such as Victor Darwin (1878–1946), a urologist from Chicago, was the first to do the intracranial intraventricular endoscopy with coagulation of the choroid plexus in two cases of hydrocephalus in 1910 (Grant 1996).

Hopkins (1918–1994) designed in 1960 the ideal system for the endoscope in form of a tube of glass with thin air lenses or rod lenses which gave later the basis of the rigid endoscope (Apuzzo et al. 1977).

Karl Storz (1911–1996), created the concept of fiber-optic in 1965 through transmitting both visual information and light in a system of glass fibers (Linder et al. 1997).

1.1.4. History of the endoscopic assisted surgery

The angled mirrors were used in the past to view the hidden areas during the operation. Later on, the endoscope was applied as an assistant tool to the operating microscope in the neurosurgical procedures to expose and visualize these hidden areas which are not vulnerable to the limited straight field of vision obtained by the microscope (Liu et al. 2001).

Pernecky documented that the endoscope can add “an improved appreciation of microanatomy not apparent with the microscope.” Meanwhile, it has been significantly used to assist the microscope in every category of the neurosurgical procedure including tumor and aneurysm surgery (endoscope-assisted microsurgery) (Pernecky and Fries 1998).

1.1.5. Endoscopic procedures

Classification of endoscopic techniques according to its role in the neurosurgical procedures:

- Pure endoscopic neurosurgery (EN),
- Endoscopic controlled microneurosurgery (ECM),
- Endoscopic-assisted microneurosurgery (EAM),
- Endoscopic inspection (EI).

(EN) uses the endoscope as the only mean of visualization with the surgical instruments introduced inside the working channels, through a single cranial hole as the entry site. (ECM) uses the endoscope as the only means of visualization also. However, the surgical instruments don't pass through the working channels but alongside the scope. (EAM) is a microneurosurgical procedure visually assisted by the endoscope to explore hidden corners. (EI) could be used in any surgical procedure only to inspect (Hopf and Perneczky 1998).

Rogers et al. divided the EAM into two categories. The first endoscopic survey, in which the endoscope is applied under microscopic control aiming to inspect the neurovascular structures as well as the borders of the lesion. The second endoscopic survey, where the endoscope is used to remove any rest tumor, to achieve full microvascular decompression (MVD), to close opened air cells at the internal auditory canal (IAC), to ensure hemostasis, or to report any neurovascular injury. Both categories are considered valuable and helpful (Rogers et al. 2000).

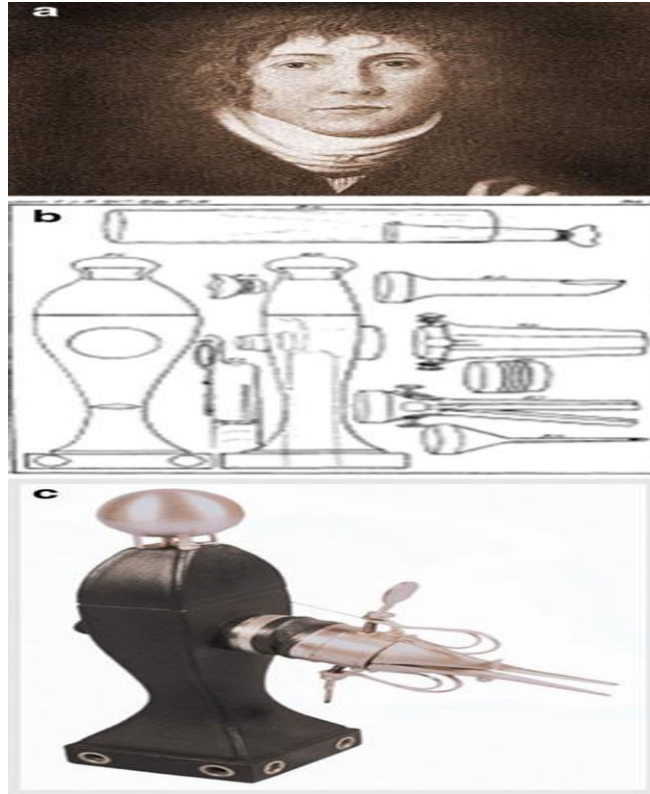


Fig. 1: History of the endoscope

(a) Philipp Bozzini (1773–1809), the ‘Godfather’ of the modern endoscope.

(b & c) Bozzini’s original design of ‘Lichtleiter’ or light carrier (Bush et al. 1974).

1.2. Anatomy

1.2.1. Anatomy of the posterior fossa

The roof of the posterior fossa is formed by the tentorium cerebelli. The tentorium separates the cerebellum below from the cerebral hemispheres above. The lateral walls and the floor are formed of parts of the sphenoid and temporal bones as well as the occipital bone where the basiocciput and the basisphenoid fused together in the midline to form the clivus. The posterior fossa lodges multiple foramina and important neurovascular structures including the cerebellar hemispheres covered with the dura which encloses various venous sinuses. Midbrain, pons, and medulla which passes through the

foramen magnum with the spinal accessory nerve, posterior spinal artery, apical ligament of the dens, membrane tectoria, and the vertebral arteries (VAs) which unit together to form the midline basilar artery (BA). The porous acoustics is the opening of the IAC transmits cranial nerves (CNs) VII, VIII, nervus intermedius, and the labyrinthine vessels. The vestibular aqueduct conveys the endolymphatic duct. The jugular foramen transmits the sigmoid sinus, the jugular bulb (pars venosa), CNs IX, X, XI, (pars nervosa) and the inferior petrosal sinus. The hypoglossal foramen transmits CN XII, a meningeal branch of the ascending pharyngeal artery, and the hypoglossal venous plexus. Emissary veins leave the posterior fossa through the mastoid foramina (Karasu et al. 2009).

1.2.2. Anatomy of the foramen magnum

The foramen magnum is a rounded bony orifice located at the base of the skull lodges several vital neuroanatomical structures. Nervous structures are cerebellar tonsils, inferior vermis, the caudal aspect of the medulla, upper part of the spinal cord covered by spinal meninges, lower cranial nerves (IX-XII), upper cervical nerves (C-1 and C-2). Vascular structures are VAs, anterior spinal arteries, posterior spinal arteries, and the meningeal branches of the VA (Fine et al. 1999).

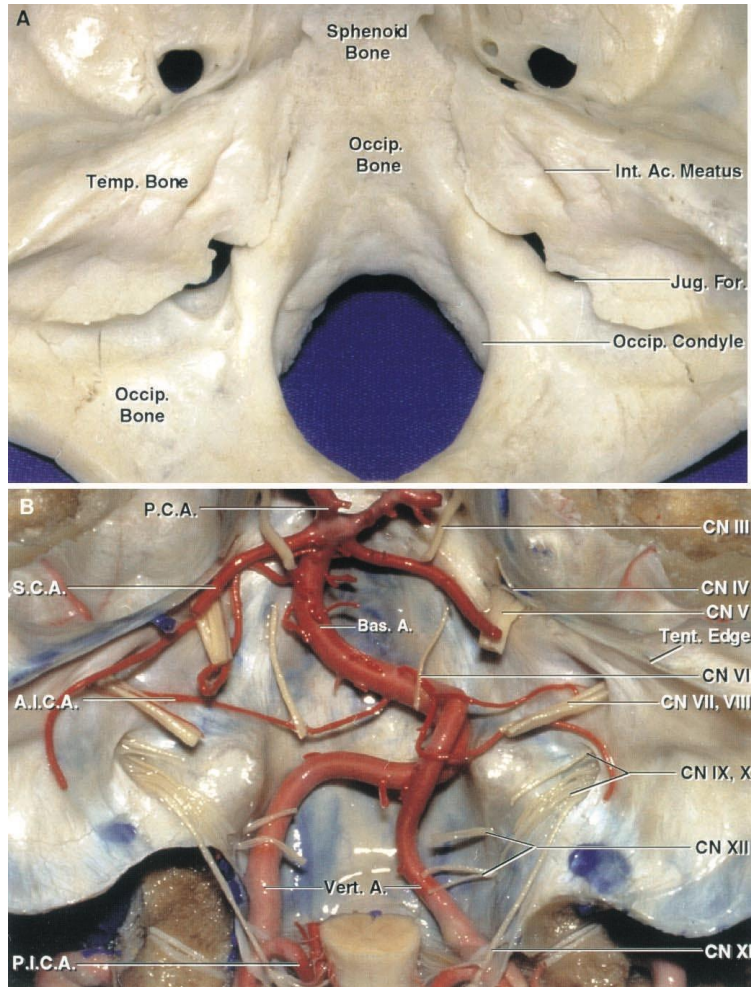


Fig. 2: Anatomy of posterior fossa.

- A. Superior view of the bony posterior cranial fossa.
- B. Nerves and arteries of the posterior fossa.

A., artery; Ac., acoustic; AICA., anterior inferior cerebellar artery; Bas., basilar; CN, cranial nerve; For., foramen; Int., internal; Jug., jugular; Occip., occipital; PCA., posterior cerebral artery; PICA., posterior inferior cerebellar artery; SCA, superior cerebellar artery; Temp., temporal; Tent., tentorial; Vert., vertebral (Rhoton 2000a).

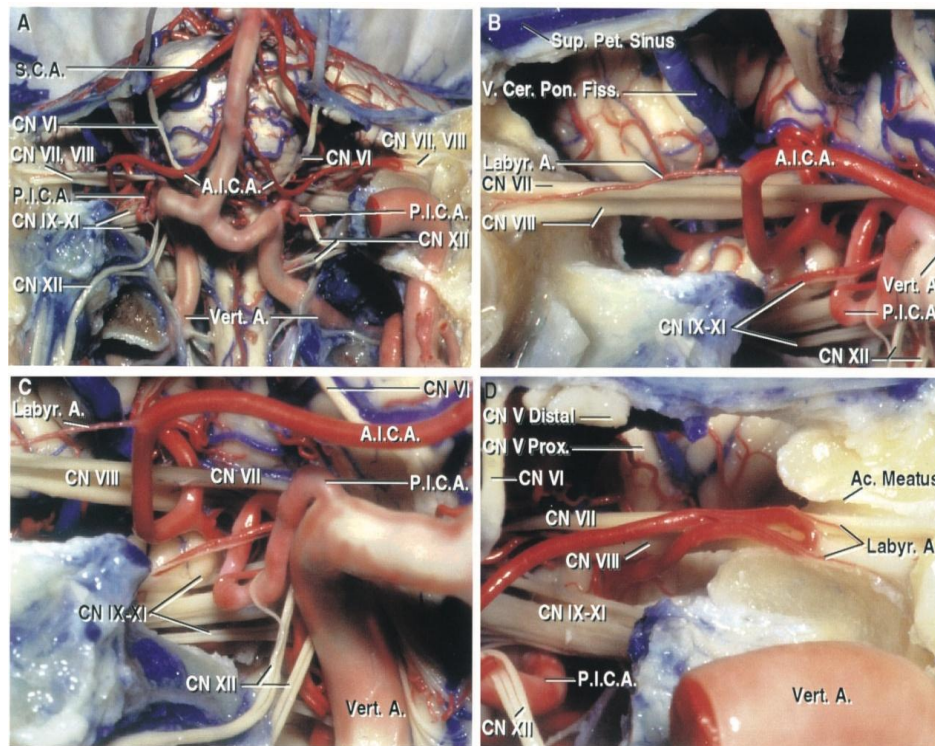


Fig. 3: Anatomy of cerebellopontine angle (CPA).

- A. Anterior view, bone is removed to expose the front of the brainstem, VA, and BA, and lower CNs.
- B. An enlarged view of the right cerebellopontine angle (CPA).
- C. Another enlarged view of the right CPA.
- D. Left posterior inferior cerebellar artery PICA and lower CNs (IX-XI and XII).

A., artery; Ac, acoustic; AICA., anterior inferior cerebellar artery; Cer. Pon., cerebellopontine; CN, cranial nerve; Fiss., fissure; Labyr., labyrinthine; Pet., petrosal; PICA., posterior inferior cerebellar artery; Prox., proximal; SCA., superior cerebellar artery; Sup., superior; V., vein; Vert., vertebral (Rhoton 2000a).

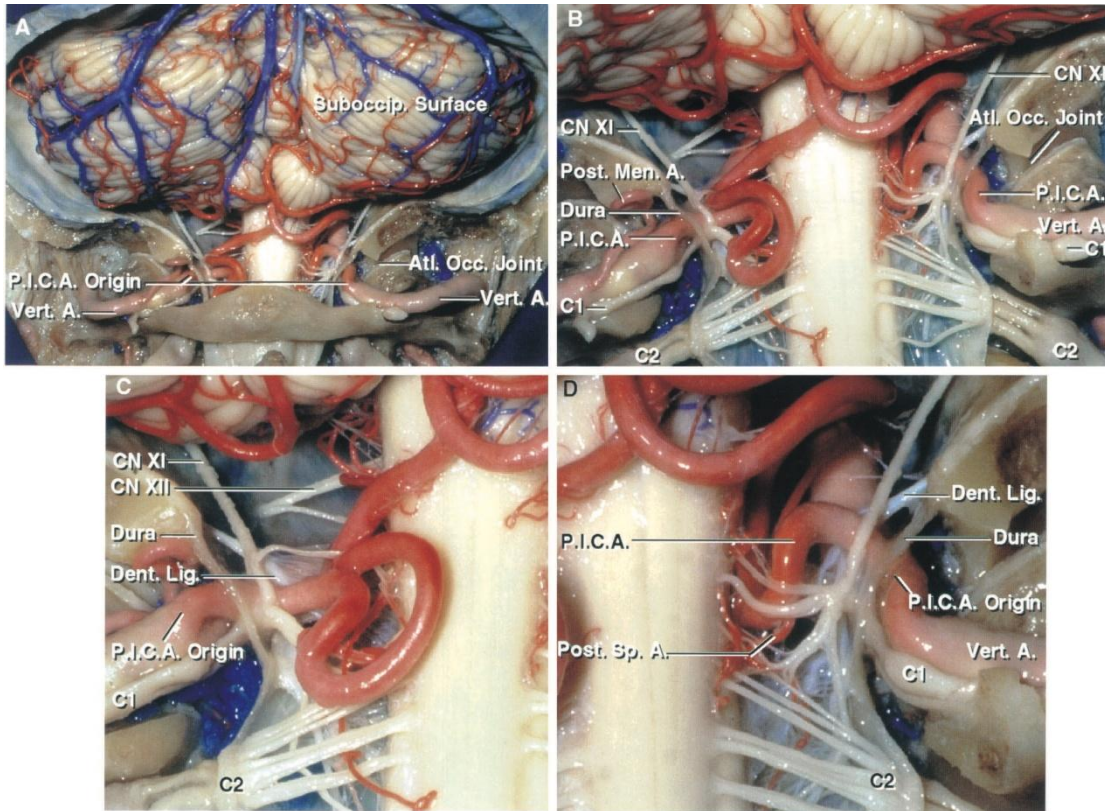


Fig. 4: Vascular anatomy of the posterior cranial fossa.

A. Both posterior inferior cerebellar arteries (PICAs) arise outside the dura as the VAs course behind the atlantooccipital joints.

B. Enlarged view. The left PICA gives off a posterior meningeal artery.

C. Left PICA penetrates the dura with the VA and the C1 nerve root. The accessory nerve passes posterior to VA and PICA.

D. C1 nerve root goes through the dura with the VA and the PICA

A., artery; Atl., atlanto; CN, cranial nerve; Dent., dentate; Lig., ligament; Men., meningeal; Occ., occipital; PICA., posterior inferior cerebellar artery; Post., posterior; Sp., spinal; Suboccip., suboccipital; Vert., vertebral (Rhoton, 2000a).

1.2.3. Anatomy of the cerebellopontine angle (CPA)

There are numbers of structures occurring in a group of three complexes (upper, middle, and lower) in the CPA. The upper complex includes the superior cerebellar artery (SCA), midbrain, cerebellomesencephalic fissure, superior cerebellar peduncle, the tentorial surface of the cerebellum, oculomotor, trochlear, and trigeminal nerves. The middle neurovascular one includes the anterior inferior cerebellar artery (AICA), pons, middle cerebellar peduncle, cerebellopontine fissure, the petrosal surface of the cerebellum, abducens, facial, and vestibulocochlear nerves. The lower neurovascular complex includes the PICA, medulla, inferior cerebellar peduncle, cerebellomedullary fissure, the suboccipital surface of the cerebellum, glossopharyngeal, vagus, spinal accessory, and hypoglossal nerve (Rhoton 2000a).

1.2.4. Anatomy of the fourth ventricle

The fourth ventricle is a diamond-shaped fluid filled cavity posterior to the pons as well as the upper part of the medulla and anterior to the cerebellum. It is connected with the third ventricle through the aqueduct and connected with the subarachnoid space through the foramen of Magendie and foramen of Luschka. Its roof is formed by the superior cerebellar peduncles and the medullary vela. Its floor is formed by the rhomboid fossa. The lateral extension of the fourth ventricle on the dorsal inferior cerebellar peduncle forms the lateral recess. The superior angle (apex) represents the upward continuation of the fourth ventricle with the aqueduct of the midbrain. The inferior angle is where the fourth ventricle extends downward into the central canal of the closed medulla (Rhoton 2000a).

1.3. Pathology

Many lesions can occur in the posterior fossa arising from the cerebellar tissue, the cranial nerves, the meninges, blood vessels, or the bony skull (Healy and Hesselink 2006).

Classification of Skull Base Diseases

Skull base lesions are classified into:

A-Congenital

B-Trauma:

Fracture and CSF leaks

C-Inflammation:

1-Infective: pyogenic, fungal, and tuberculosis

2-Noninfective: sarcoidosis and Wegener's granulomatosis

D-Tumors:

1-Nonepithelial: meningioma, neurofibroma, schwannoma, and their malignant counterparts.

2-Metastasis

E-Vascular:

1-Aneurysms

2-Vascular malformations (Laine et al. 1990).

2. Aim of the work

The purpose of this work is to assess the advantages of using the endoscope as an adjuvant tool during microsurgical management of posterior fossa lesions. We paid particular attention to the effectiveness and safety of the endoscope.

3. Patients and methods

A retrospective study is done in the period from February 2010 until March 2015 at the Department of Neurosurgery, Eberhard Karls University Hospital, Tübingen, Germany to analyze the advantages of the endoscope as an assistant tool to the operating microscope for posterior fossa surgery. We selected for the current study, 85 patients with different lesions in the posterior fossa, whom underwent endoscopic-assisted surgery via various transcranial approaches.

Inclusion criteria

Inclusion criteria were as follows:

- Patients with different lesions of the posterior fossa.
- Patients treated with EAM.
- Patients with newly discovered pathology.
- Patients with previously operated pathology (recurrent lesions).

Exclusion criteria

Exclusion criteria were as follows:

- Follow-up period is shorter than three months.
- Patients treated with only microsurgical technique.
- Patients treated through a trans-oral approach.

3.1. Retrospective data collection

A retrospective chart review was conducted to identify all patients, whom were treated with the endoscopic-assisted technique for lesions in the region of the posterior fossa. Microsoft Excel (Microsoft Excel 2010, Microsoft, USA) is used to standardize the data in a table form. The following data were collected from the database system of the hospital charts, clinical reports, and operations databank SAP (SAP System R/3, SAP Germany AG & CO. KG, Germany):

- *Age of the patient at time of surgery,
- *Date of birth,
- *Gender,
- *Preoperative history and first symptom duration (Symptomatology),
- *Physical findings (Neurological examination),
- *Intraoperative video recordings and images from endoscope,
- *Intraoperative video recordings and images from microscope,
- *Operative reports,
- *Pre- and postoperative radiological findings,
- *Intensive Care Unit (ICU) charts,
- *The follow-up data are obtained for all patients including:
 - Histopathological results,
 - Adjuvant treatments,
- *Outcome:
 - Lesion control
 - Improvement of the presenting symptoms
 - Detection of new symptoms
- *Complications:
 - Immediately postoperative (during the patient's stay in our ICU and ward).
 - Late complications (after discharge from the hospital during a postoperative follow-up period ranged from 3 months to 3 years in our outpatient clinic with regular clinical and radiological evaluations).

3.1.1. Patients data

Personal data such as name, age, sex, date of surgery are collected from the memory disk of the endoscope and compared with the database of the operations to select the patients, whom underwent endoscopic assisted posterior fossa surgery. Data of the patients are secured keeping the rights of the patients.

3.1.2. Pathology

Patients are classified into two broad groups according to the nature of lesions in the posterior fossa including:

I- Tumour group:

- Vestibular schwannoma (VS)
- Trigeminal schwannoma
- Epidermoid cyst
- Clival lesions
- Fourth ventricle tumors
- Brain stem tumors
- Foramen magnum tumors

II- Non-Tumour group:

- Aneurysm
- Trigeminal nerve pathology (neuralgia / infection)
- Hemifacial spasm (HFS)
- Cerebrospinal fluid (CSF) leak and fistula repair

3.1.3. Preoperative management

3.1.3.1 Clinical assessment

All patients are evaluated before surgery with documenting the history of the present illness through analyzing the offending complaint/ complaints, general examination, assessment of medical fitness, and complete neurological examination.

3.1.3.2 Investigations

Radiological studies in the form of; with and without contrast computed tomography (CT) scan of the brain with bone window, CT angiography as well as with and without gadolinium-enhanced magnetic resonance imaging (MRI) could be accessed through Centricity Web (Centricity Web 3.0, Centricity PACS 3.0, USA). Through this program, we had the ability to check the preoperative, postoperative, and follow-up control images.

Preoperative investigations included recordings of facial motor evoked potential (MEP), electromyography (EMG), brainstem auditory evoked potential (BAEP), and pure tone audiometry (PTA) were done for particular cases.

3.1.4. Operative approaches

Particular attention was paid to the value of the endoscope as an adjuvant tool to the operating microscope during the microsurgical procedure regarding visualization, time of the technique as well as postoperative morbidity and mortality resulted from the endoscopic-assisted technique.

Suboccipital retrosigmoid, median suboccipital, pterional, far lateral, and subtemporal approaches were done in either supine, concorde, park bench or semisetting positions under general anesthesia with intraoperative neuromonitoring (IOM) (Somatosensory Evoked Potential (SEP), BAEP, MEP, and EMG of the facial nerve).

3.1.4. Postoperative follow-up and complications

All patients were subjected postoperatively to regular clinical assessment to evaluate either improvement or deterioration of the clinical symptoms and received as well postoperative CT brain to exclude any postoperative pathology.

Regular follow-up evaluation with MRI brain with and without contrast is done to detect complete removal, residual tumor, or recurrence. Follow-up data are collected from the medical reports of each patient's file in the database including immediate post-operative follow-up in ICU, daily follow up in the ward, and regular outpatient follow-up. Focusing on the state of the initial complaint, appearing of the new symptoms, residual, or recurrence of the lesion.

In cases of VS and Epidermoid cyst, the surgical results and outcomes, including hearing function and facial nerve function were evaluated at the last follow-up day. The facial nerve was assessed pre- and postoperatively by the House-Brackmann (HB) grading system. The visual analog scale (VAS) was used for pain assessment. In cases of vascular lesions, clipping of an aneurysm was controlled intraoperatively by indocyanine green (ICG) and postoperative by the radiological investigation as CT brain and angiography. Diagnosis of each space occupying lesion (SOL) in the tumor group was confirmed histologically in each case.

3.2. Surgical tools

Surgeries were performed with the microscope and the rigid endoscope with continuous IOM. The surgeon could smoothly introduce the angled optics into the operative field under direct microscopic control.

3.2.1. Essential tools

1-Endoscope:

Bayonet rigid endoscope with 0°, 30°, and 45° optics (Karl Storz, Tuttlingen, Germany). Irrigation systems, endoscope holding arm, light source, Coupled Charged Device (CCD) camera, monitor, and video recorder. The endoscope was connected via a fiber-optic cable, to a xenon light source as well as a video camera which fixed with three charge-coupled device sensors and attached to a video monitor to support the high resolution of the images.

Rigid endoscopes are less flexible than fiberscope that's why it needs a viewing angle for the surgical procedures. However, they provide high-quality pictures and make bimanual procedures much more possible. Images and videos were taken and recorded using a digital video recorder system.

2-Microscope:

(Pentero OPMI, Karl Zeiss, Oberkochen)

3-Instruments:

Microsurgical instruments.

3.2.2. Additional tools

1-Drill

2-Intra-operative monitoring (IOM)

3-Cavitron Ultrasonic Surgical Aspirator (CUSA)

4-ICG

5-Doppler ultrasound (US)

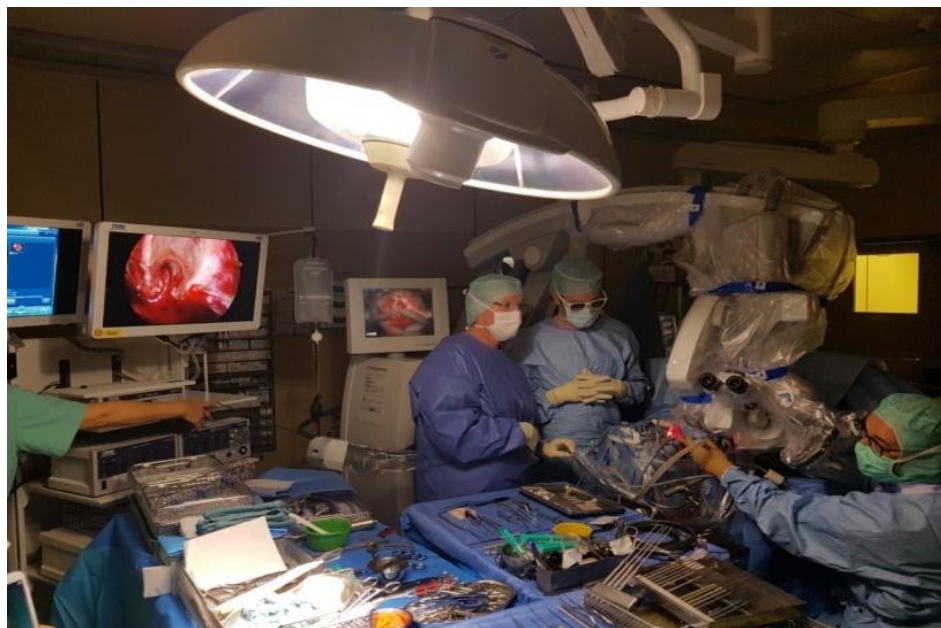

Fig. 5: Operation room setup, klinik für Neurochirurgie Universitätsklinikum Tübingen.

4. Results

4.1. Analysis of patients' data

4.1.1. Patient characteristics

4.1.1.1. Sex

A total number of 85 patients underwent endoscopic assisted microsurgery for posterior fossa was conducted in the present study. 37 patients were males (43.5%) and 48 patients were females (56.5%) with the male-to-female ratio was 1:1.3.

4.1.1.2. Age

The mean age of patients in this study at the time of surgery was 47.24 years (SD \pm 13.99) (range 8-75y). The mean age of male patients was 48.95 years (SD \pm 10.3) while the mean age of female patients was 48.09 years (SD \pm 10.6).

4.1.2. Pathology

2 broad groups of the different pathologies of the posterior fossa are further classified into:

I- Tumour group (71 Patients) (84.5 %)

- VS (40 patients)
- Epidermoid cyst (17 patients)
- Clival tumors (5 patients)
- Fourth ventricle tumors (3 patients)
- Brain stem tumors (3 patients)

- Foramen magnum tumors (2 patients)
- Trigeminal schwannoma (1 patient)

II- Non-Tumour group (14 Patients) (15.5 %)

- Aneurysm (6 patients)
- Trigeminal neuralgia (6 patients)
- HFS (1 patient)
- CSF leak and fistula repair (1 patient)

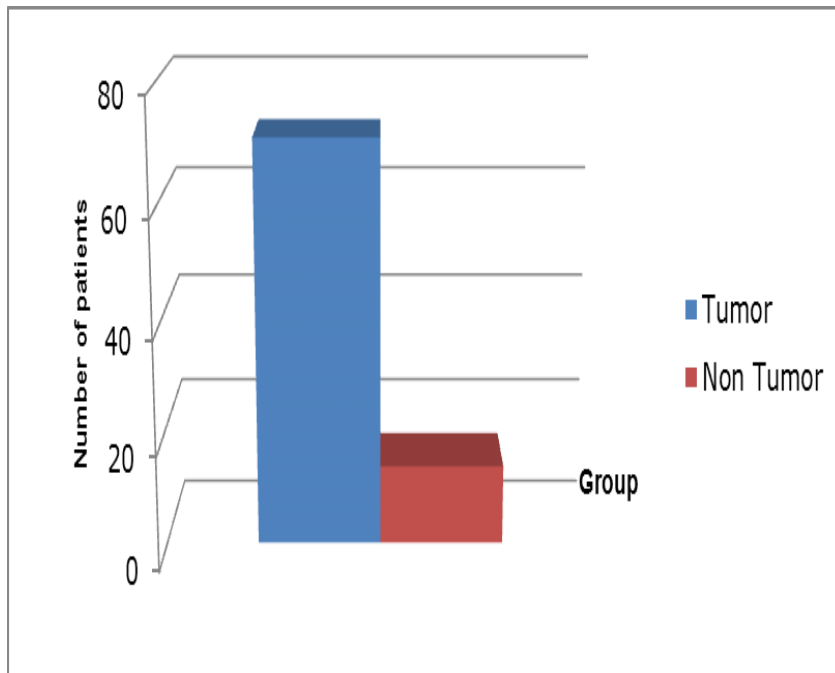


Fig. 6: Groups of the patients.

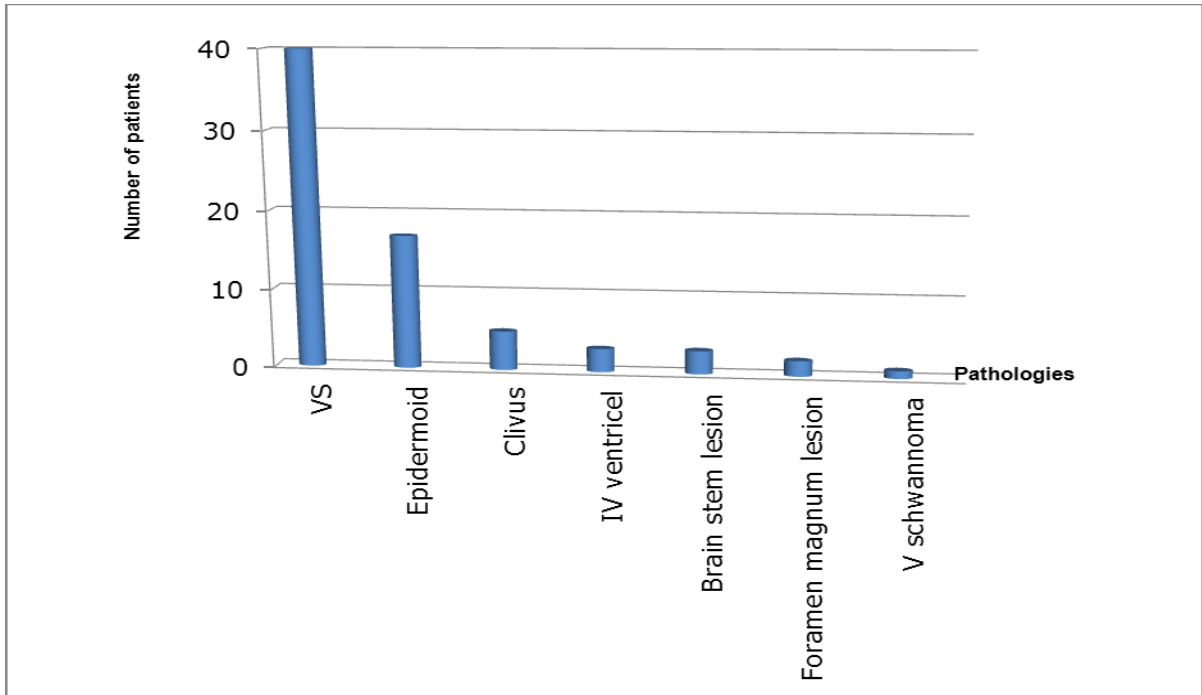


Fig. 7: Different pathologies of the tumor group.

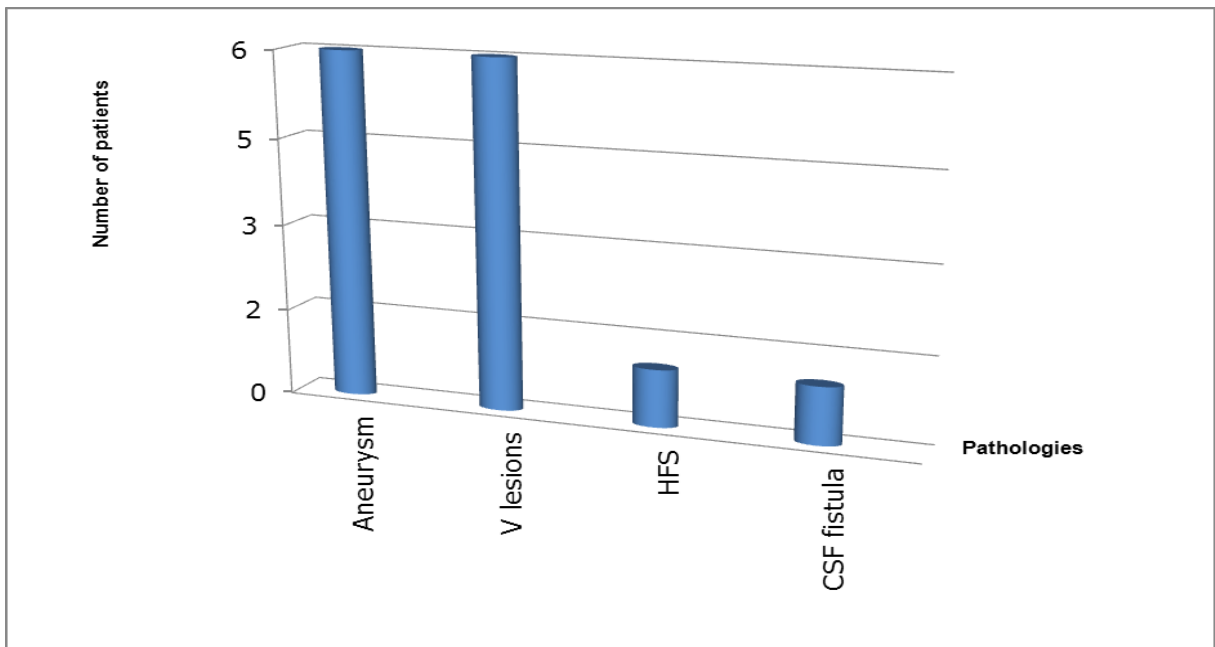


Fig. 8: Different pathologies of the non-tumor group.

4.1.2.1. Previous surgery

7 cases had a previous surgical treatment and were recorded as recurrent pathology (8.2%), while 78 patients were recorded for the first surgical treatment (91.8%).

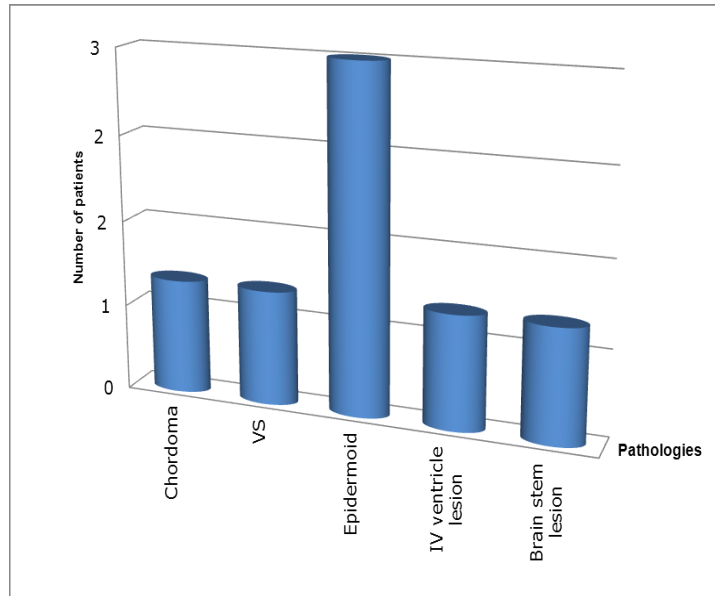


Fig. 9: Cases of recurrent pathology.

4.1.2.2. Location

The pathology involved the left side in 37 patients (43.5%), the right side in 38 patients (44.8%), and the midline in 10 patients (11.7%).

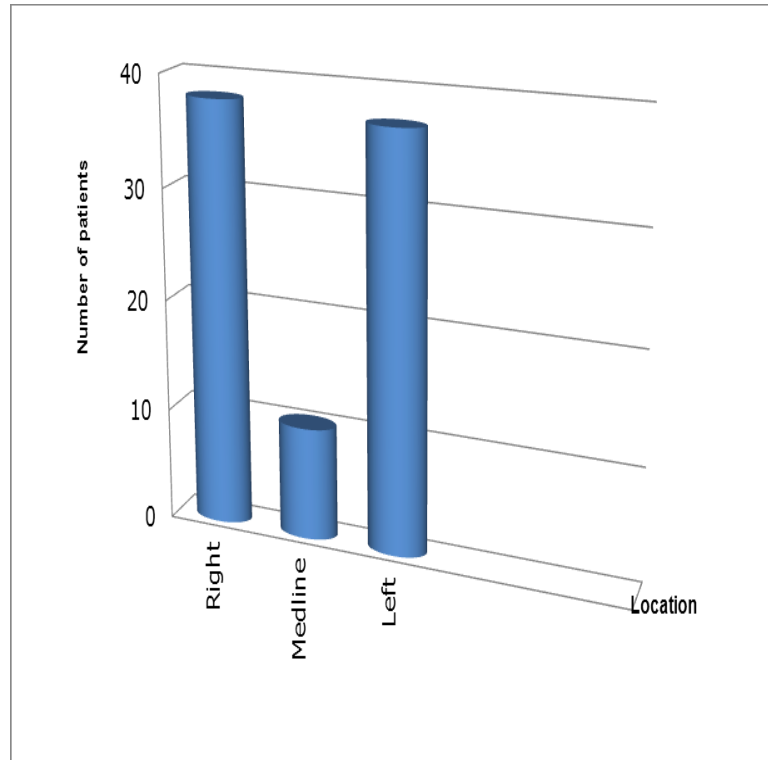


Fig. 10: Side of the lesions.

4.1.3. Clinical presentation

The duration of symptoms ranged from 2 months to 30 months. Vertigo was recorded as the most common presenting symptom in the majority of patients (52.9%) followed by diminution of hearing in (51.7%) of patients. All symptoms are described below.

| | | Symptoms | | | | | | | | | | | | | | |
|--------------------|------------------------|----------|---------|----------|-----------------|--------------------|----------|-----------------------|-----------------|-------|-----|----------|----------------|----------------|--------------|-----------|
| | | Diplobia | Vertigo | Headache | Trigeminal pain | Lower CNS symptoms | Tinnitus | Hearing deterioration | Facial weakness | Nusea | SAH | CSF leak | Speech problem | Motor weakness | Facial spasm | Neck pain |
| Number of patients | | 7 | 51 | 11 | 14 | 3 | 23 | 48 | 9 | 6 | 5 | 1 | 1 | 1 | 1 | 1 |
| Pathologies | Clival lesions | 2 | 1 | 1 | 1 | 1 | | | 1 | | | | | | | |
| | VS | | 35 | 2 | 1 | | 20 | 40 | 2 | 4 | | | | | | |
| | Epidermoid cyst | 3 | 12 | 4 | 5 | | 3 | 8 | 4 | 1 | | | | | | |
| | IV ventricle lesions | 2 | 2 | 2 | | | | | | 1 | | | | | | |
| | Foramen magnum lesions | | | 2 | | | | | | | | | | | | |
| | Brain stem lesions | | 1 | | | 2 | | | 2 | | | | 1 | 1 | | |
| | Trigeminal Pain | | | | 7 | | | | | | | | | | | |
| | Postoperative fistula | | | | | | | | | | | 1 | | | | |
| | HFS | | | | | | | | | | | | | | 1 | |
| | Aneurysm | | | | | | | | | | 5 | | | | | 1 |

Tab. 1: Presenting symptoms of each lesion.

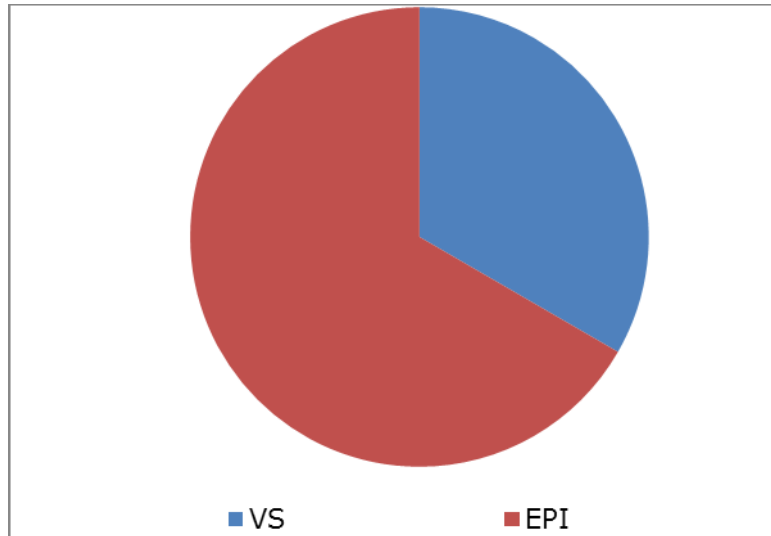


Fig. 11: VII affection in cases of VS and epidermoid cyst.

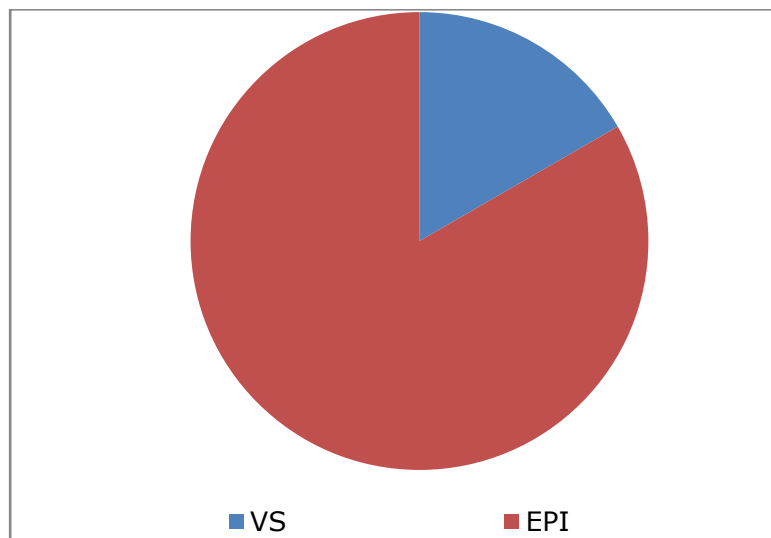


Fig. 12: V affection in cases of VS and epidermoid cyst.

| Preoperative HB grade | Number of patients |
|--------------------------|-----------------------|
| II | 6 |
| III | 2 |
| IV | 1 |

Tab. 2: Preoperative HB grade.

| Postoperative HB grade | Number of patients |
|---------------------------|-----------------------|
| II | 11 |
| III | 3 |
| IV | 5 |

Tab. 3: Postoperative HB grade.

| Preoperative HH grade | Number of patients |
|--------------------------|-----------------------|
| I | 2 |
| II | 1 |
| III | 2 |
| IV | 0 |

Tab. 4: Preoperative Hunt und Hess grade.

4.2. Surgical approaches

Transcranial approaches in various positions were used to manage the patients with different pathologies in the region of the posterior fossa.

The approaches were:

- Suboccipital retrosigmoid (72 cases) (84.7%)
- Median suboccipital (8 cases) (9.4%)
- Pterional (3 cases) (3.5%)
- Farlateral (1 case) (1.2%)
- Subtemporal approach (1 case) (1.2% Case).

The positions were:

- Supine position: 57 cases (67%)
- Semisetting position: 20 cases (23.5%)
- Concorde position: 7 cases (8.3%)
- Bark pench position: 1 case (1.2%)

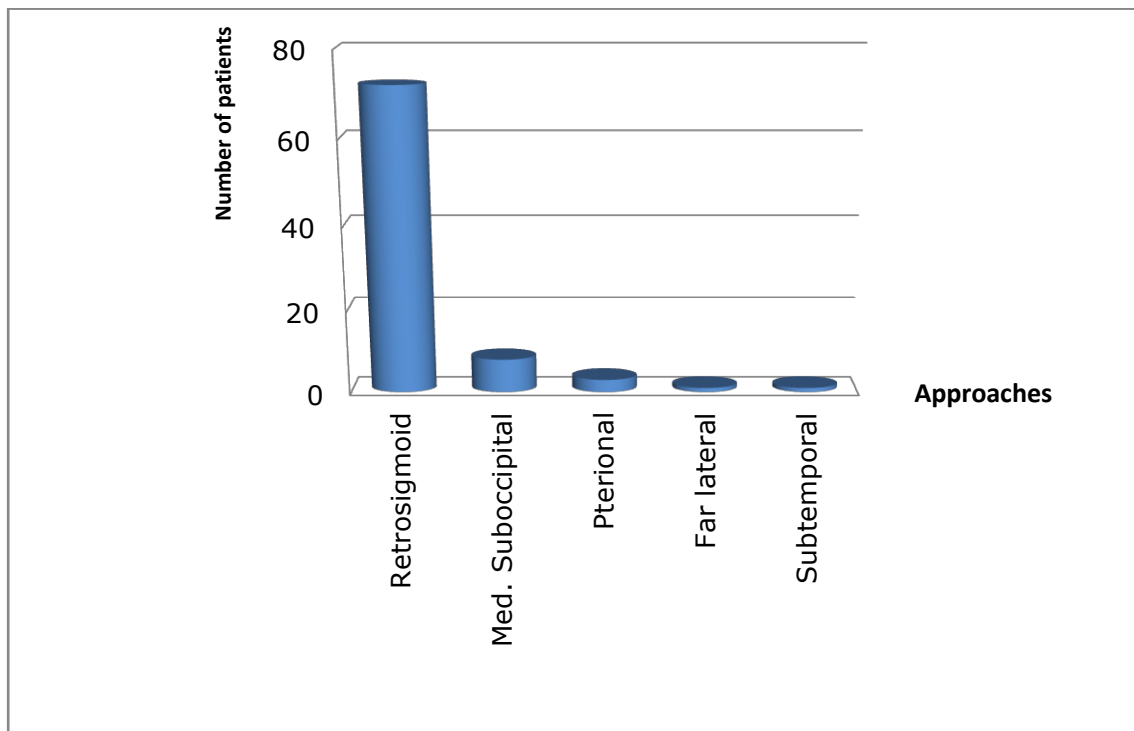


Fig. 13: Different approaches for the posterior fossa.

Retrosigmoid suboccipital approach

The retrosigmoid suboccipital approach was done for 72 patients in either supine position (54 patients) or semisitting position (18 patients).

The endoscope was introduced under the guidance of the microscope after complete microsurgical removal of the tumor to inspect:

- 1- The CPA, to visualize the neurovascular structures nearby the tumor.
- 2- The IAC, to look for residual tumor at the fundus of the canal or to detect opened bone air cells, which in turn could be closed under direct endoscopic vision using bone wax.

Or the endoscope was used to recheck the actual compressing vessel around the Root Exit Zone (REZ) of V or VII after microvascular decompression (MVD) as well as confirming the optimum placement of the Teflon patch.

At the end of the procedure, the functional integrity of the facial nerve was confirmed by stimulation.

Median suboccipital approach

Patients are positioned under general anesthesia in either semisitting position (1 patient) or concorde position (7 patients).

Entering between the cerebellar tonsils gives the access to the fourth ventricle. Identification of PICA on both sides, the region of the obex, base of the fourth ventricle, and the stria medullary. Or retracting the cerebellar tonsils and proceeding in the depths to reach the dura of the clivus, exposing and

visualizing critical neurovascular structures such as brain stem, VA, and lower CNs.

After microsurgical subcapsular dissection, debulking of the tumor, or microscopic identification of the aneurysm, the endoscope was introduced into the surgical field under the control of microscope to inspect the tumor cavity to exclude any residual tissue, capsular adhesions, blood oozing, or safe clipping of the aneurysm.

Far lateral approach

In the semisitting position and following a slight retraction of the cerebellum with a spatula the hypoglossal nerve and the VA can be exposed and visualized.

The endoscope is introduced under the guidance of microscope after microscopic debulking of the tumor to visualize the neurovascular structures as well as the hidden corners to exclude residual tumor which not seen by the operating microscope. This approach was applied for 1 patient.

Pterional approach

3 patients were operated in the supine position. The Sylvian fissure is opened under the microscope then two brain spatulas are subsequently applied to expose the ipsilateral optic nerve. The optic cistern is opened to evacuate clear liquor. The BA can also be visualized.

The Endoscope was introduced to expose the anatomy and to identify the lesion enabling the surgeon to look around the corners and to rotate with endoscope obtaining full view rather than the limited straight line of vision of the microscope.

Subtemporal approach

Retraction of the uncus by the retractor tip to expose the opening into the interpeduncular cistern. Elevation of the uncus with the tip of the retractor facilitates the elevation of the third nerve. Opening of the arachnoid just above the SCA under CN III lateral to the midbrain, proceeding anterior to CN III allowing the carotid and the posterior communicating arteries to be freer reducing the force of retraction to reach the PCA above the CN III. Following the SCA backward below the third nerve to see the BA. This approach was used for 1 patient.

The endoscope was introduced to get better images of the PCA, BA, and perforating arteries to ensure the clipping procedures.

4.3. Outcome of endoscopic-assisted surgery

The duration of postoperative observation in our ICU was 24 hours for all patients who showed uncomplicated postoperative recovery. Only 2 patients (2.3%) had recorded 14 and 20 days of postoperative stay in ICU. On the other side, the average number of days for staying in the neurosurgical ward recorded as 7 days, with only 1 patient (1.2%), who had stayed for 30 days due to meningitis.

26 patients (30.5 %) had at least 3 months of postoperative follow-up. 13 patients (15.5%) had 6 months of postoperative follow-up, 23 patients (27%) had one year of postoperative follow-up, 14 patients (16.5 %) had 2 years of postoperative follow-up, and 9 patients (10.5 %) had 3 years of postoperative follow-up.

The median follow-up duration in the current study was 12.9 months (range from 3 months to 36 months).

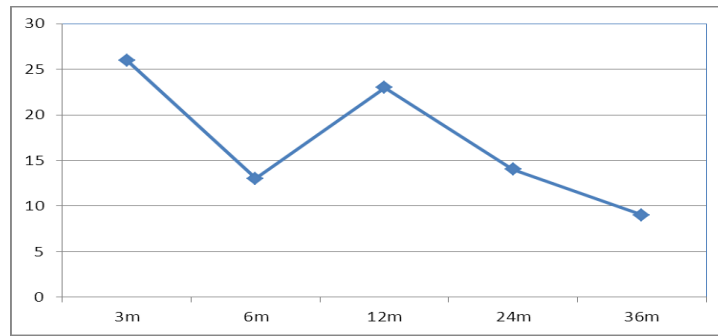


Fig. 14: Follow-up time in months.

The present study had revealed the following data:

4.3.1. Tumor group:

4.3.1.1. Vestibular schwannoma

In 40 cases of VS, the anatomical integrity of the cochlear nerve was preserved in 100% of patients with maintaining the preoperative levels of hearing in 34 patients (85%).

| Postoperative hearing follow up | Number of Patients | percent |
|---------------------------------|--------------------|--------------|
| Improved | 1 | 2.5% |
| No change | 33 | 82.5% |
| Deteriorated | 6 | 15% |

Tab. 5: Postoperative hearing follow-up in cases of VS.

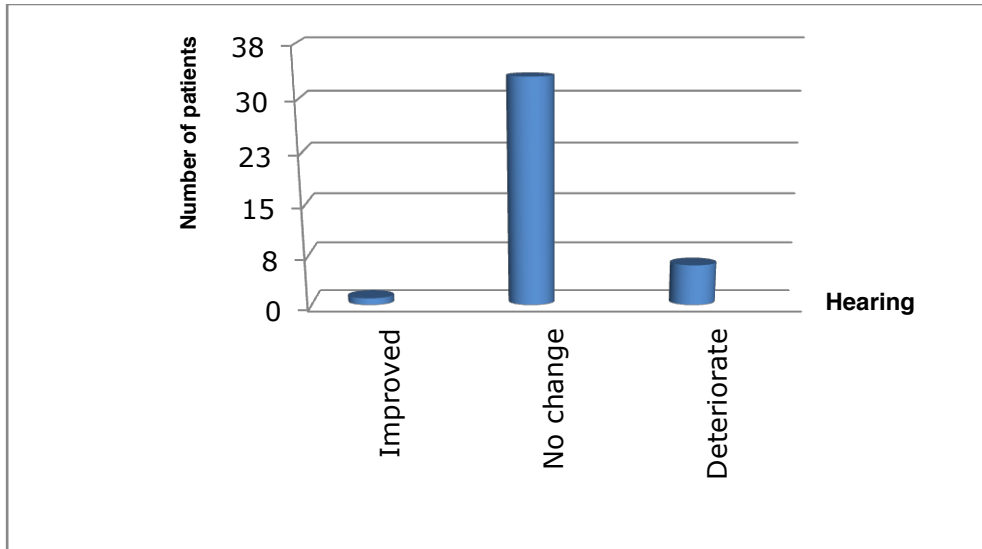


Fig. 15: Postoperative hearing follow-up in cases of VS.

The preoperative MRI showed variable sizes of the lesions which classified according to Hannover's classification into:

- T1: 9 Patient (22.5%)
- T2: 23 Patient (57.5%)
- T3b: 5 Patient (12.5%)
- T4a: 3 Patient (7.5%)

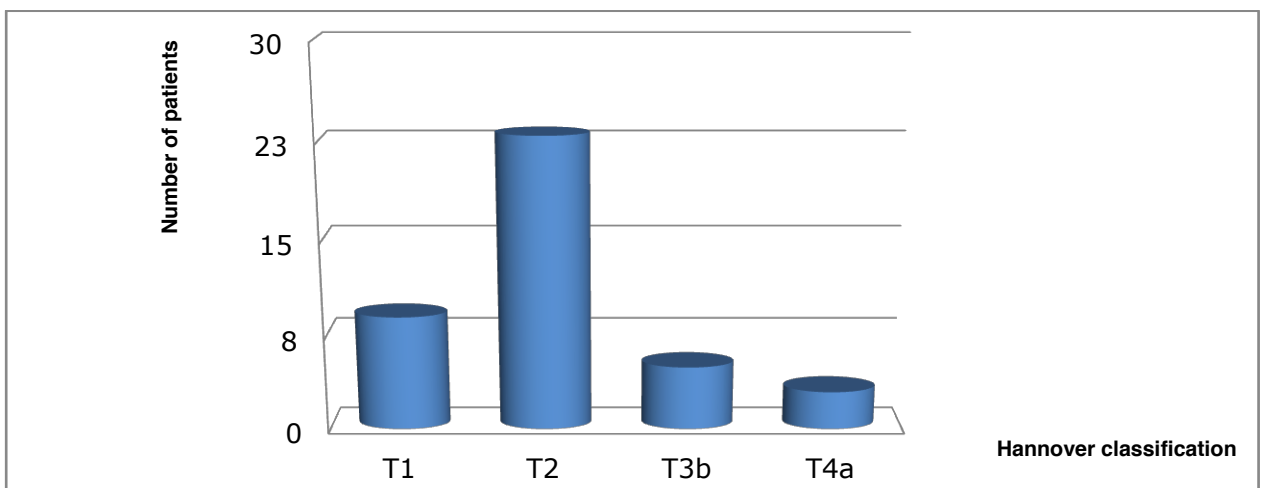


Fig. 16: VS according to Hannover's classification.

11 patients (27.5%) were operated in semisitting position and 29 patients (72.5%) in supine position via retrosigmoid approach. 39 patients were the first time to undergo surgery and 1 case was recurrent.

Inspection with the endoscope provided the operator and in short time with very vital additional informations, which not given initially by the view of the microscope such as:

- 1- Identification of residual tumor in the fundus of IAC, which not seen by the microscope in 12 patients (30%).
- 2- Detection of opened mastoid air cells with the subsequent application of bone wax was achieved with the assistance of endoscope in 20 patients (50%).
- 3- Inspection with the endoscope under the guidance of the microscope confirms performing the surgical job of complete removal of the schwannoma.

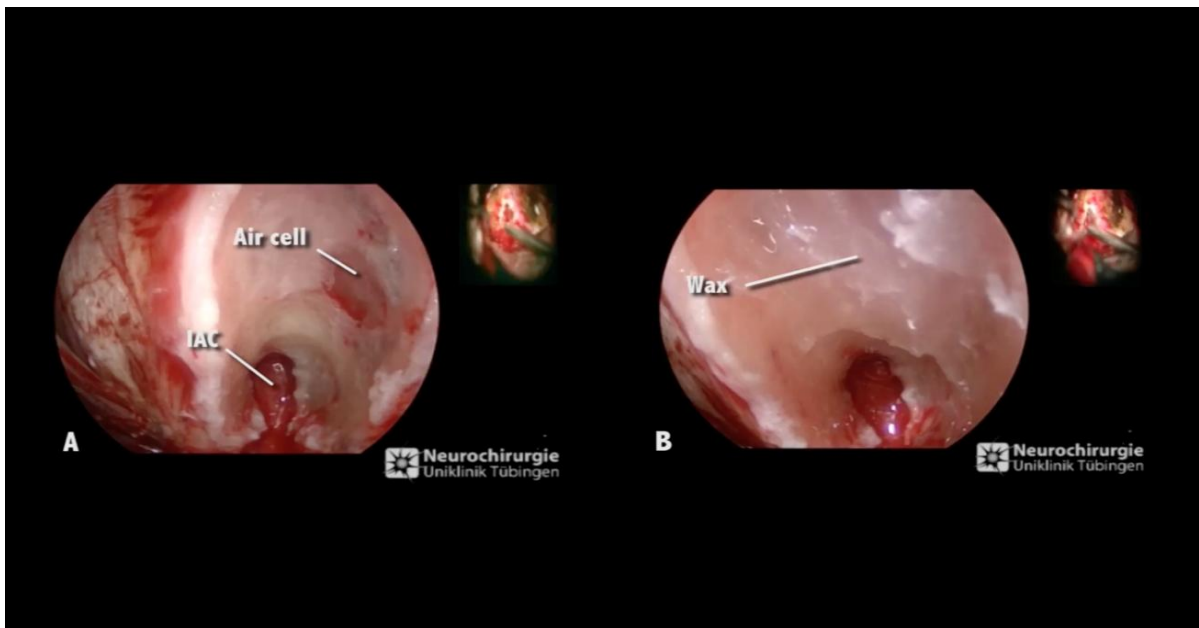


Fig. 17: Management of opened mastoid air cells in endoscopic assisted technique.

A: Detection of the opened mastoid air cells

B: Waxing of opened mastoid air cells.

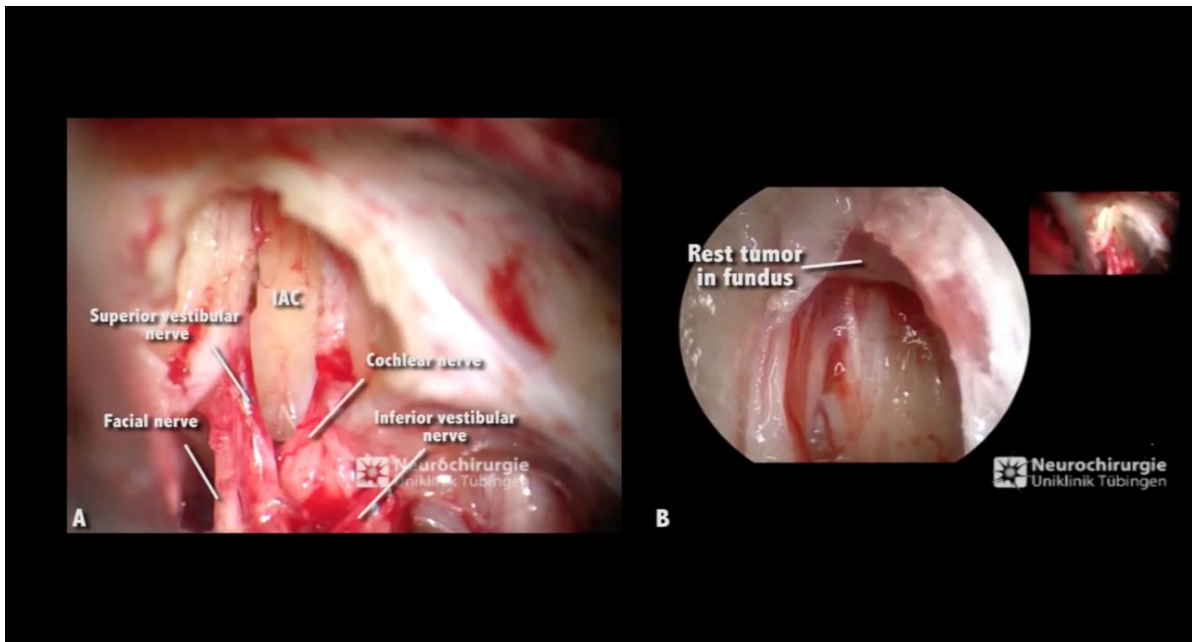


Fig. 18: Detection of rest tumor which not seen initially by the microcope.
 A: Microscopic view: after microsurgical removal of the tumor.
 B: Endoscopic view: after microsurgical removal of the tumor (rest tumor).

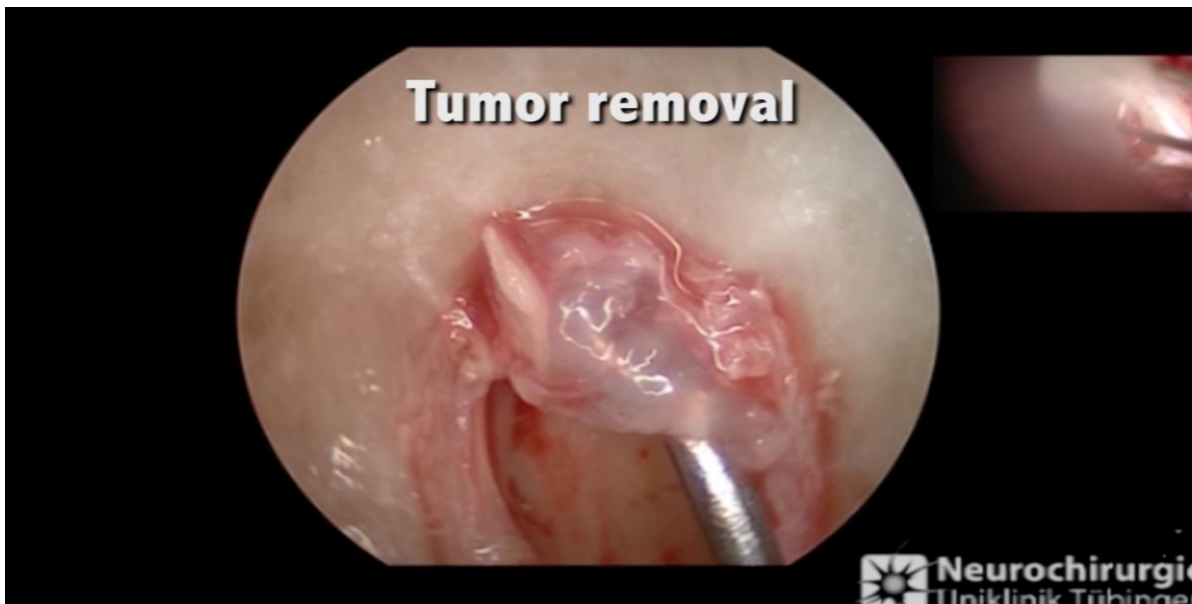

Fig. 19: Resection of rest tumor in EAM.

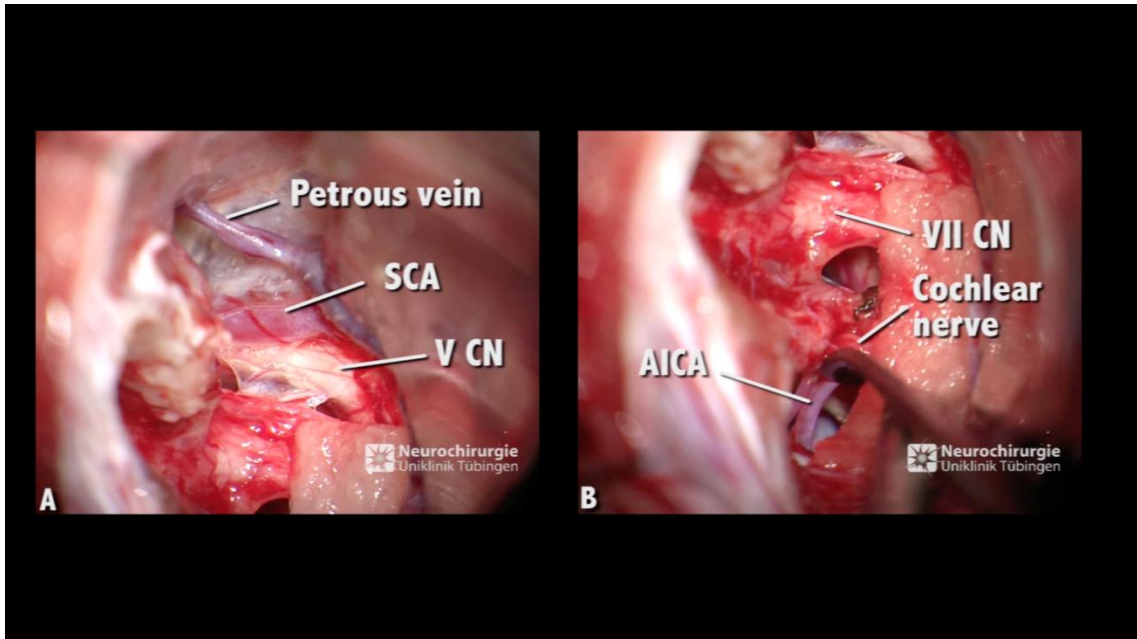


Fig. 20: Microscopic view after removal of the tumor.

A: Microscopic view of the upper part of CPA.

B: Microscopic view of the lower part of CPA.

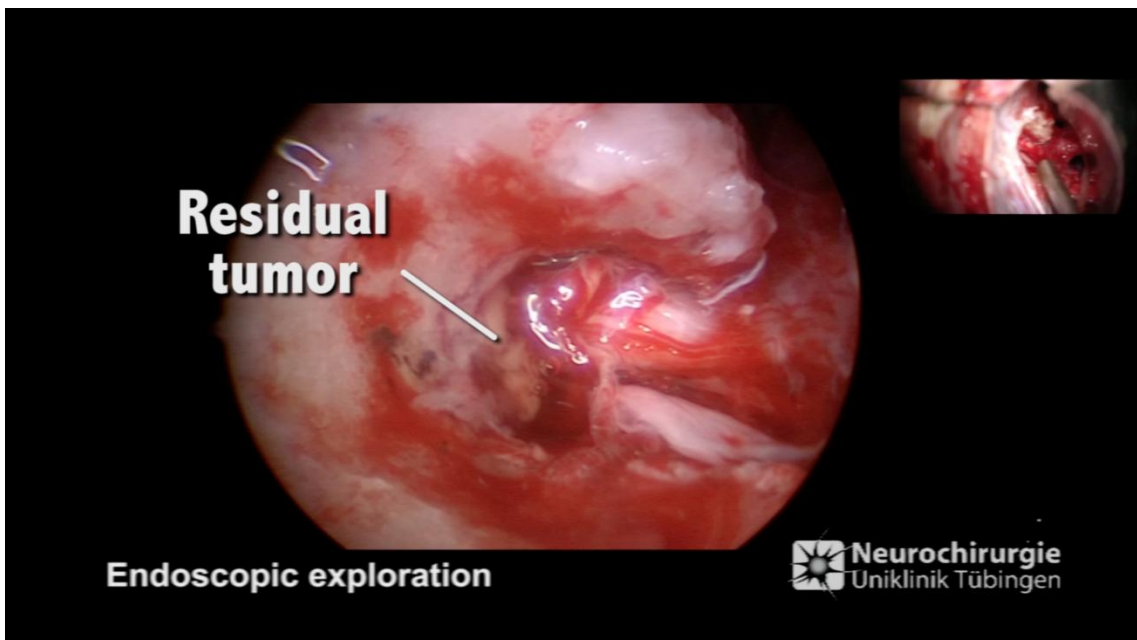


Fig. 21: Detection of residual tumor after the microscopic removal of the tumor in another case.

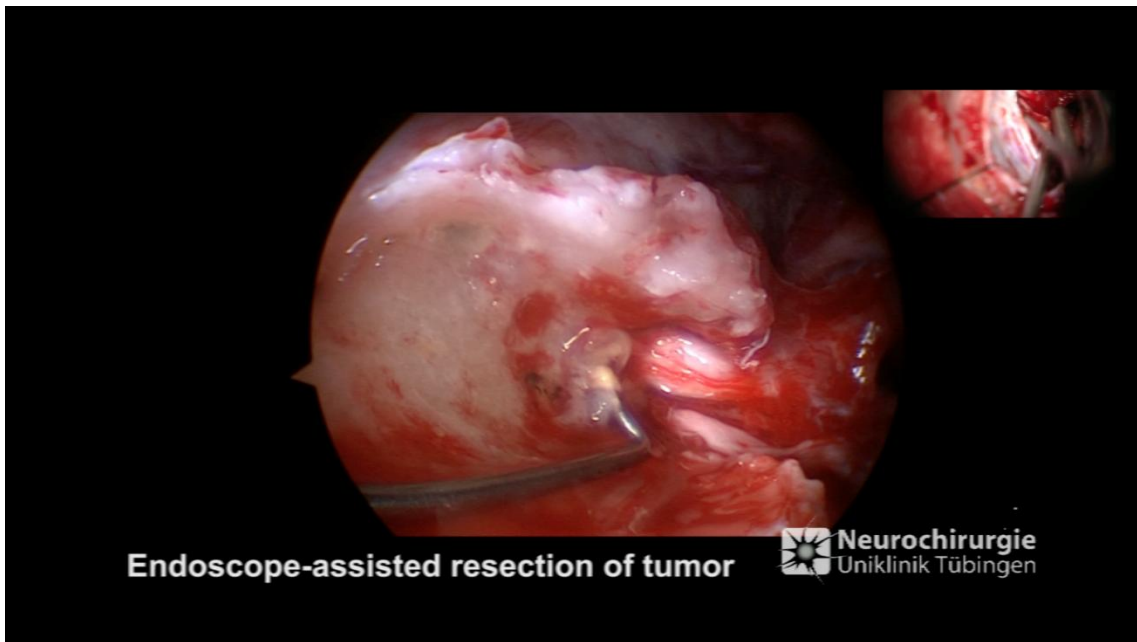


Fig. 22: Endoscopic view: Rest tumor resection.

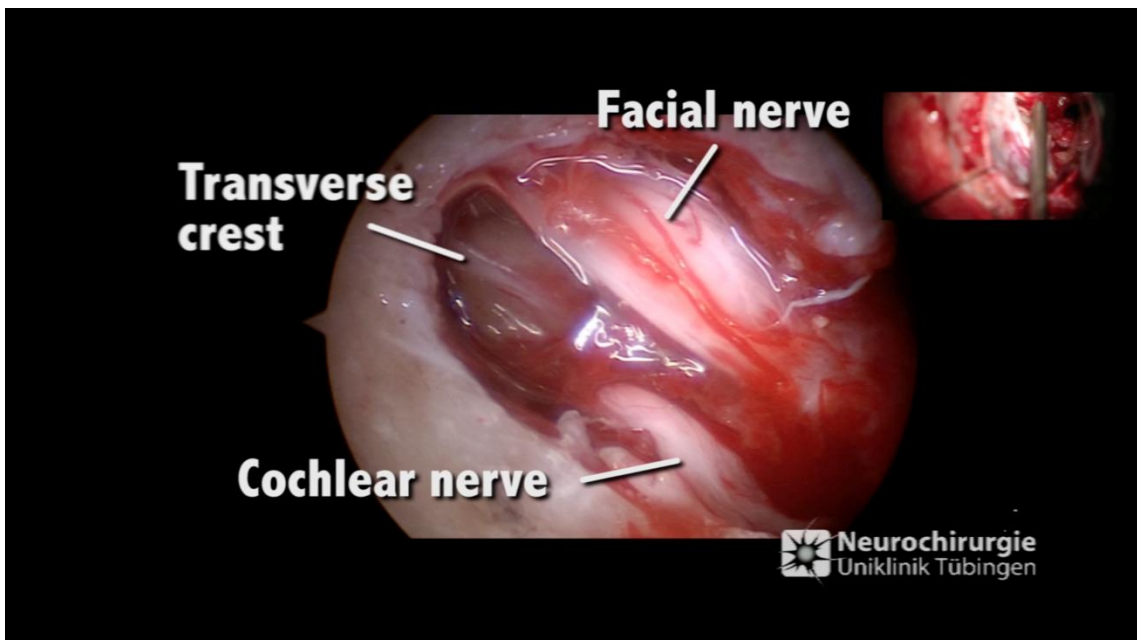


Fig. 23: Endoscopic view after the endoscopic-assisted removal of the tumor.

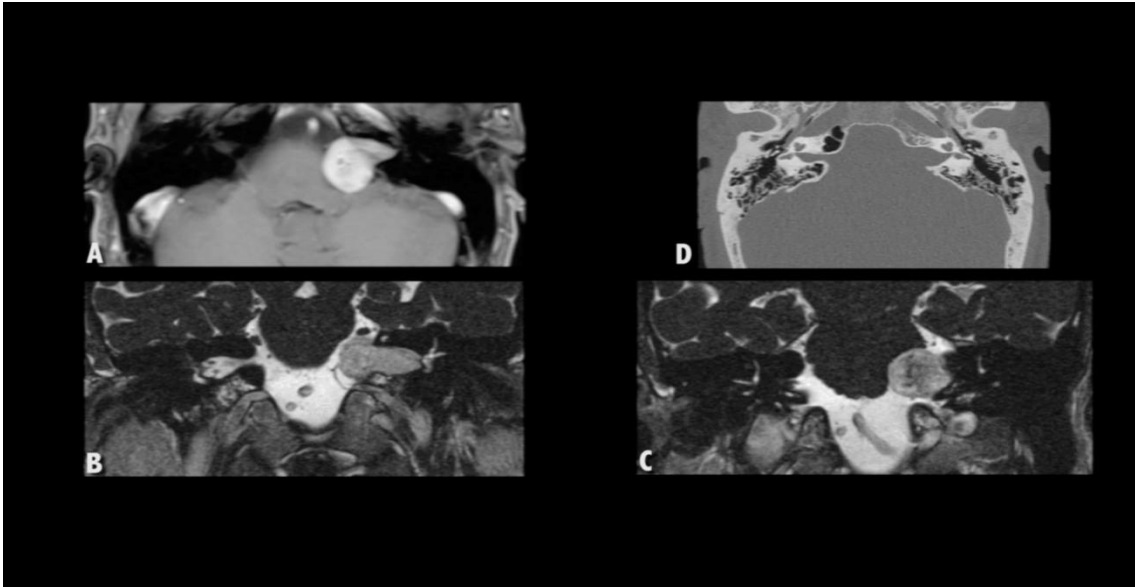


Fig. 24: Preoperative images of left VS.

A: T1 axial view, with contrast showing left T3 VS.

B: T2 coronal view, with contrast showing left intracanalicular part of the T3 VS.

C: T2 coronal view, with contrast showing brain stem compression.

D: Preoperative CT.

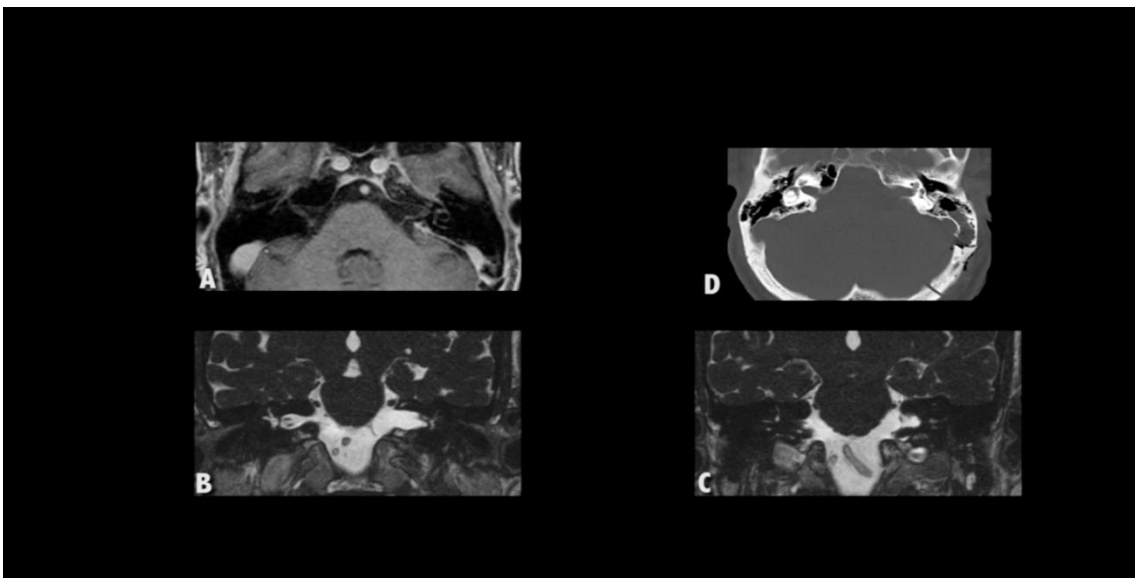


Fig. 25: Postoperative images (immediate CT and follow-up MRI after 6m)

A: T1 axial view, with contrast showing complete removal of the tumor.

B: T2 coronal view, showing complete removal of the tumor.

C: T2 coronal view, showing complete removal of the tumor.

D: Immediate postoperative CT, showing the IAC and small craniotomy.

Total elimination of the lesions was confirmed in 39 cases (97, 5%) with the follow-up MRI. The histopathological examination in all cases revealed Schwannoma grade I. No complications from the endoscope were recorded.

Immediate postoperative follow up revealed:

*13 cases (32.5%) had postoperative facial palsy in the form of:

-HB IV: (1 patient)

-HB III: (3 patients)

-HB II: (9 patients)

*8 cases (20%) of disturbance of balance.

*6 cases (15%) of deterioration of hearing.

*3 cases (7.5%) of persistent tinnitus.

*1 case (2.5%) of meningitis.

*2 cases (5 %) of postoperative CSF fistula:

-1 case improved with lumbar drainage (LD).

-1 case needed surgical intervention.

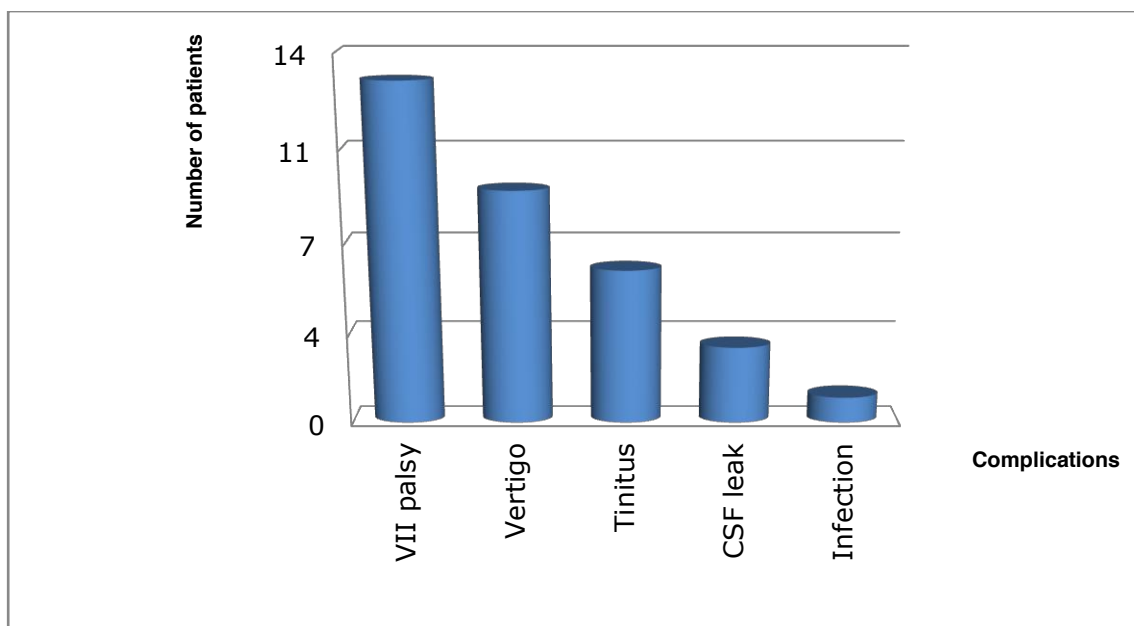


Fig. 26: Immediate postoperative follow up in cases of VS.

4.3.1.2. Trigeminal schwannoma

The anatomical integrity of the trigeminal nerve was preserved in 100 % of patients.

1 Patient with trigeminal nerve schwannoma was operated in supine position via retrosigmoid approach. The endoscope was very helpful in the total uncomplicated removal of the neuroma. No postoperative complications were detected.

4.3.1.3. Epidermoid cyst

In 17 cases of CPA epidermoid cyst, 2 patients (11.7%) were operated in semi-setting position and 15 patients (88.3%) in supine position via retrosigmoid approach. 14 patients were subjected to first-time surgery, while 3 cases were recurrent.

Inspection with the endoscope offered us the opportunity to get superior additional views which are not given initially by the microscope during the current surgery or the previous surgery such as:

- 1- Visualization of CNs III till VII in 3 patients (17.6%).
- 2- Visualization of any residual of the tumor including supratentorial extension as well as dissection the capsule from the neurovascular structures (neurolysis) in 16 patients (94.1%).
- 3- Confirming total removal of the lesion in 2 patients (11.8%).

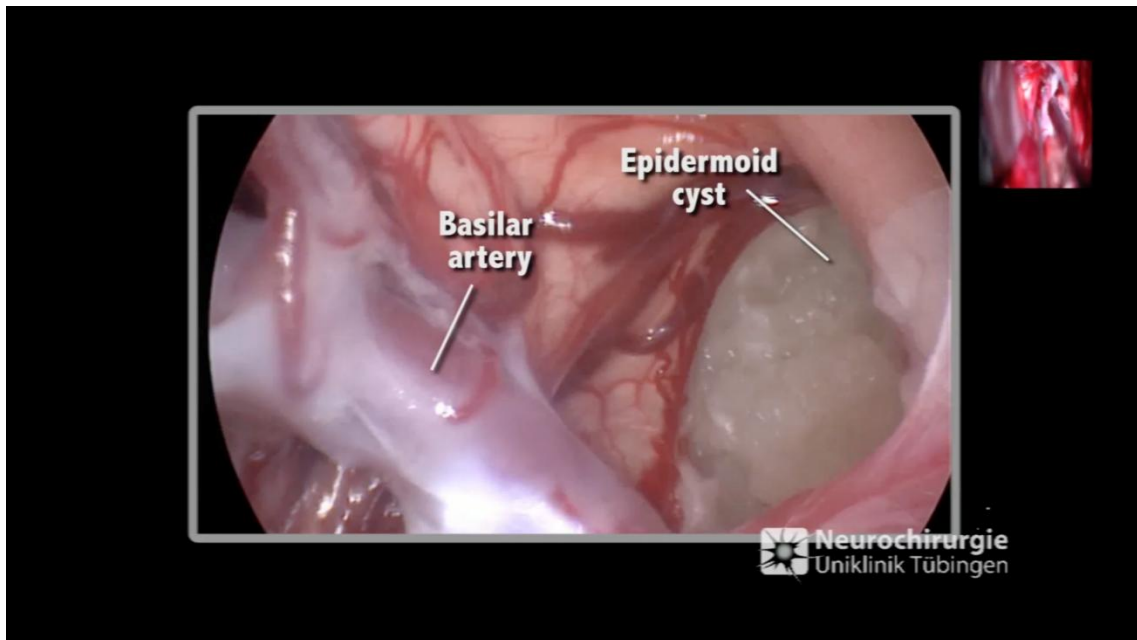


Fig. 27: Endoscopic view under microscopic control detecting rest of the tumor.

Total removal of the lesion was confirmed in 15 patients (88.3%) in the follow-up MRI. The histopathological examination in all cases revealed epidermoid cyst. No thermal complications from the endoscope were recorded in our study. However, a mechanical injury to the trochlear nerve in one patient was occurred.

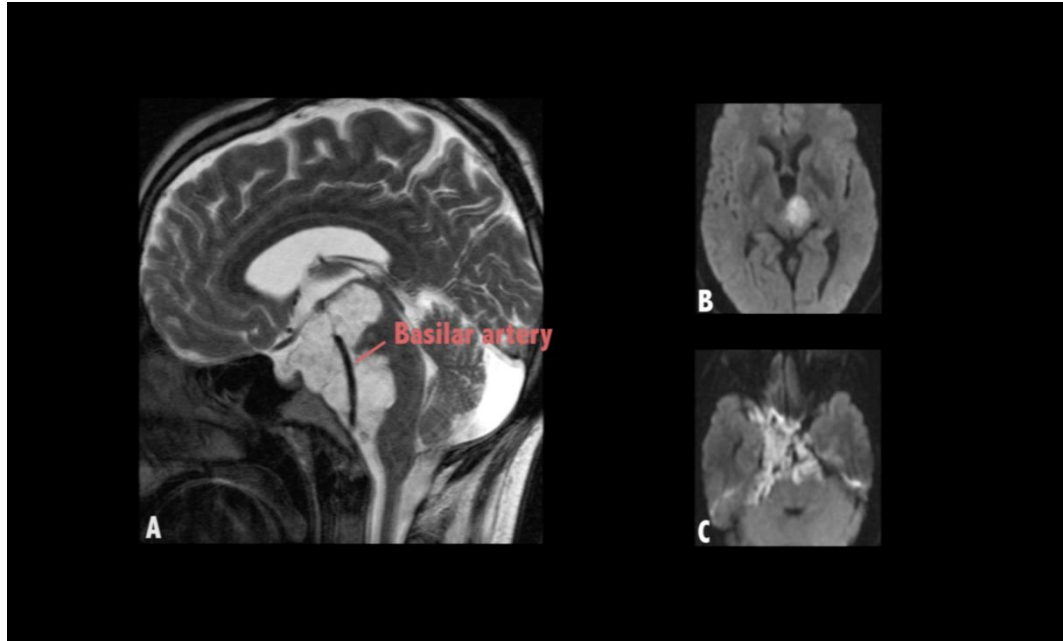


Fig. 28: Preoperative images of epidermoid cyst.

A: T2 sagittal view, showing large epidermoid cyst encasing the BA.
B & C: Diffusion weighted image (DWI) showing the extentions of the epidermoid cyst.

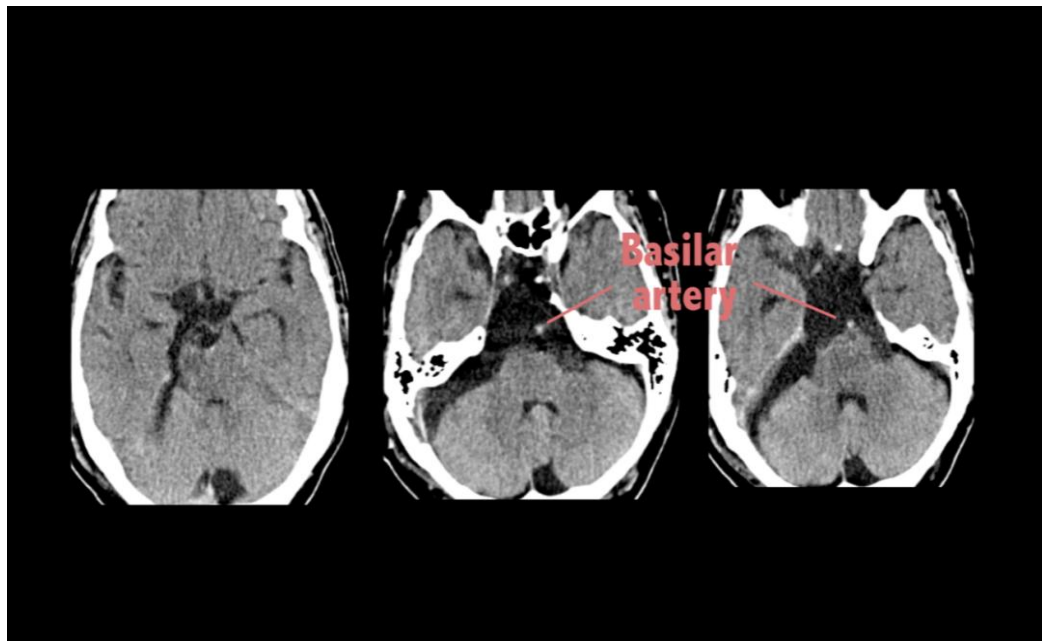


Fig. 29: Postoperative CT showing total removal of the tumor with intact BA

Immediate postoperative follow-up showed:

*5 cases (29.4%) of postoperative facial palsy in the form of:

-HB IV: 3 patients (17.7%) only one patient needed a sural graft

-HB II: 2 patients (11.7%).

*8 cases (47%) of balance disturbance.

*3 cases (17.7%) of recurrent pathology detected after one year.

*2 cases (11.7%) of postoperative CSF fistula:

-1 case improved with LD.

-1 case needed surgical intervention.

*1 case (5.8%) of CN VI injury.

*1 case (5.8%) of lower CN affection.

*1 case (5.8%) of deterioration of hearing.

*1 case (5.8%) of CN IV injury and this was the only recorded complication from the endoscope in our study.

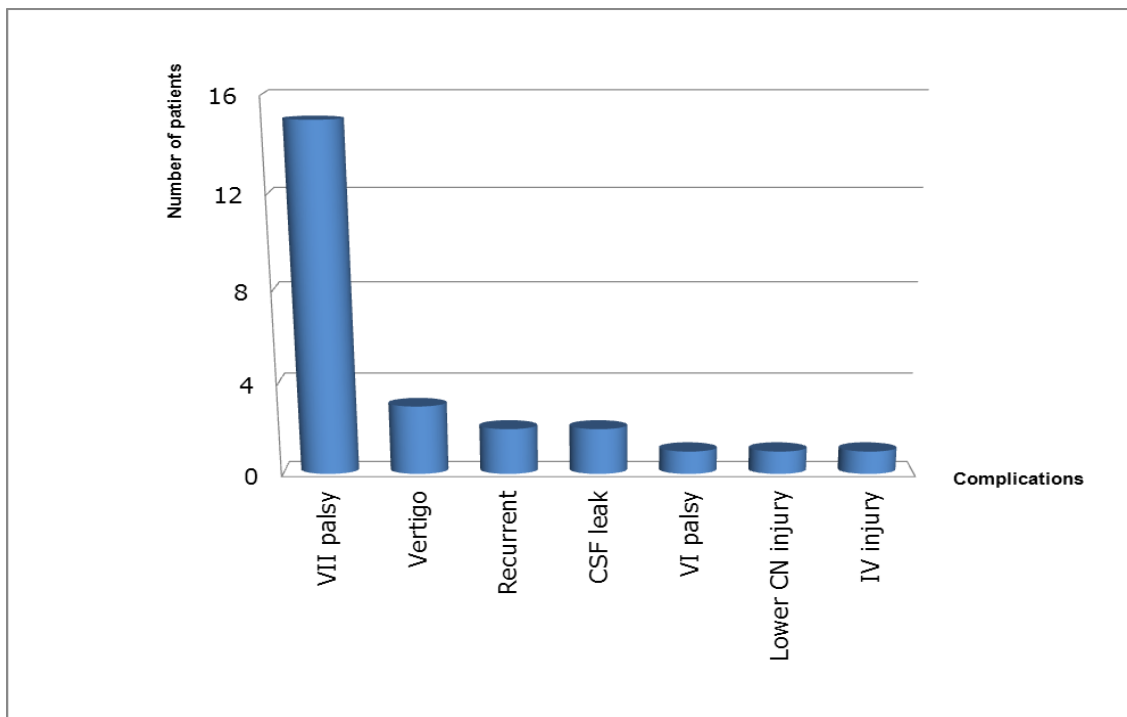


Fig. 30: Immediate postoperative follow up in cases of epidermoid cyst.

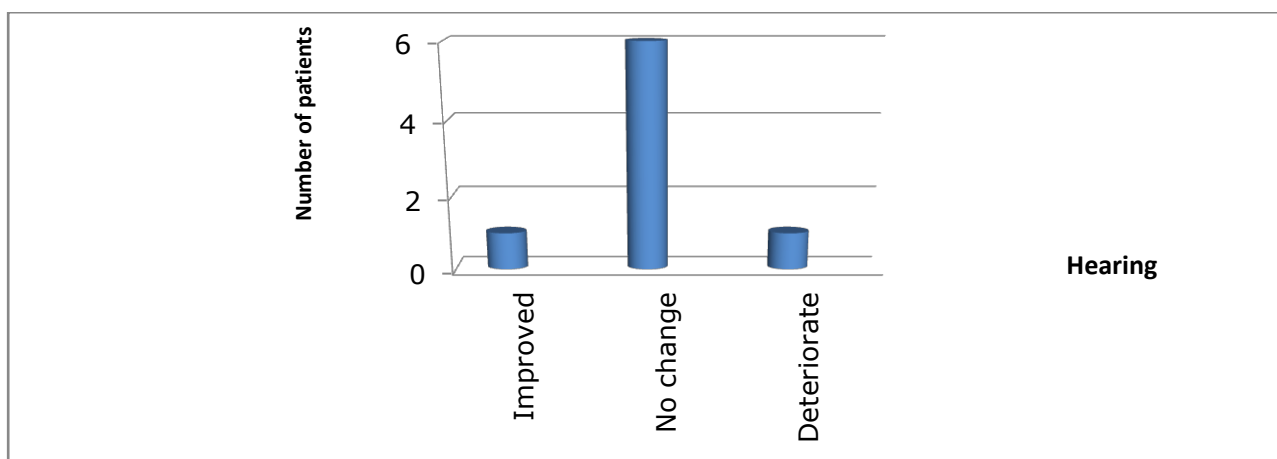


Fig. 31: Postoperative hearing follow-up in cases of epidermoid cyst.

4.3.1.4. Clival tumors

A total number of 5 patients with clival lesions were operated via median suboccipital approach (2 patients), retrosigmoid approach (2 patients), and far lateral approach (1 patient). 1 patient was recorded with a recurrent lesion.

Inspection with the endoscope gave the surgeon the ability to look around the corners as well as to evaluate the relationship between the tumor and the vital neurovascular structures helping to do either partial resection - because of potential risk to injury the neurovascular structure in 2 patients- or confirming total removal of the tumor in 3 patients. Complete removal of the lesion was confirmed in the follow-up MRI (60%).

*The histopathological examination revealed:

- Meningotheliomats meningioma grade-I,
- Secretory meningioma grade-I,
- Transitional meningioma grade-I,
- Chondrosarcoma grade-II,
- Chordoma.

No thermal or mechanical injuries from the endoscope were recorded. 3 patients (60%) had a postoperative residual tumor, which was seen by the endoscope and left due to adhesions. The endoscopic inspection was useful to decide when exactly to stop doing further radical removal thus, achieving maximum possible removal. Postoperative follow up showed:

* 1 case (20%) of facial palsy HB IV.

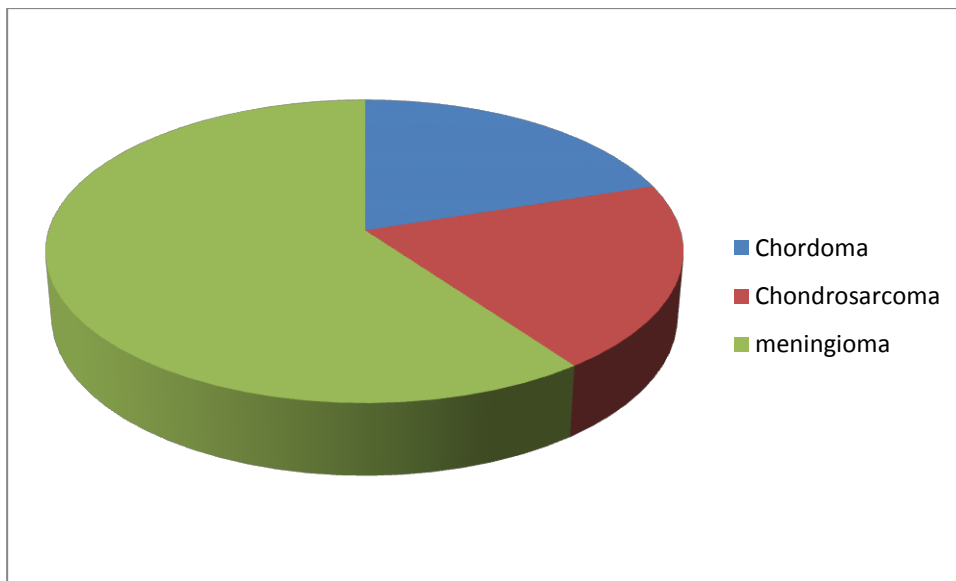


Fig. 32: Clival lesions.

4.3.1.5. Brain stem tumors

3 cases of brain stem lesions were operated in semisetting position via retro sigmoid approach. 1 patient was recorded with a recurrent lesion.

Inspection with the endoscope confirmed the total removal of the lesion in 2 cases (66.6%) and helped in the detection of a residual tumor in 1 case (33.3%). Complete excision of the lesion was confirmed in the follow-up MRI in 2 cases (66.6%).

*The histopathological examination revealed:

- 1 case cavernoma,
- 1 case schwannoma (vagus),
- 1 case glioma grade VI.

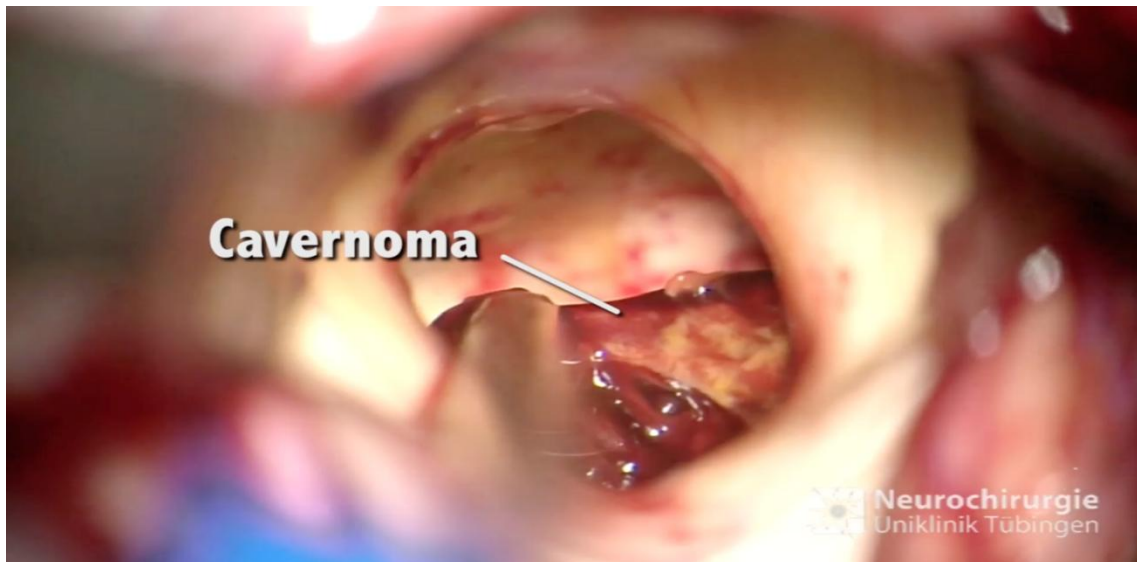


Fig. 33: Microscopic view: removal of the cavernoma.

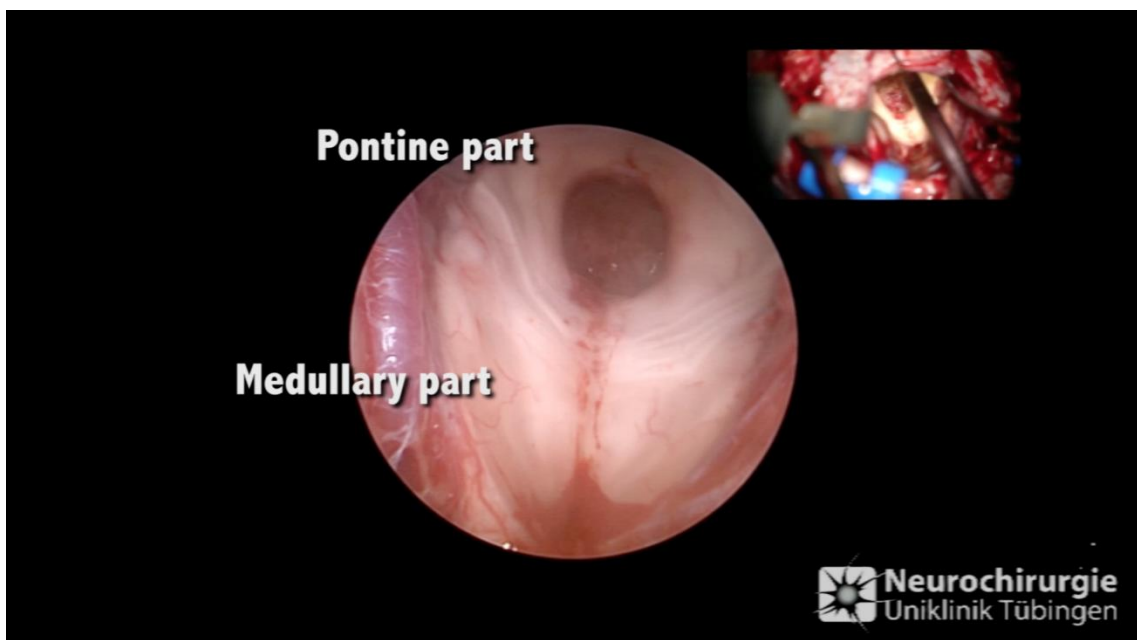


Fig. 34: Endoscopic inspection under microscopic control detecting no residual of the cavernoma.

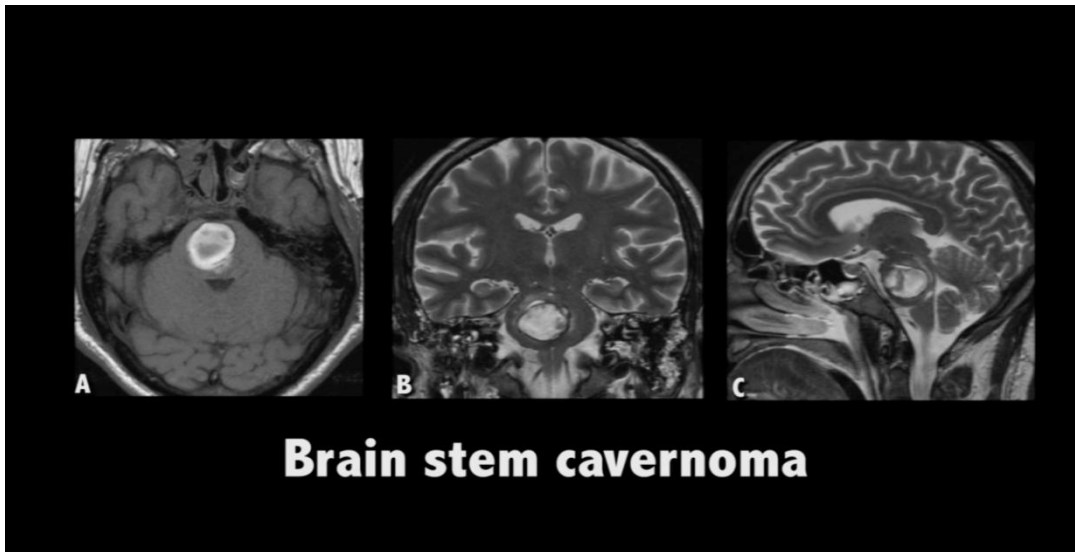


Fig. 35: Preoperative MRI.

A: T1 axial view, with contrast showing pontine cavernoma

B: T2 coronal view.

C: T2 sagittal view.

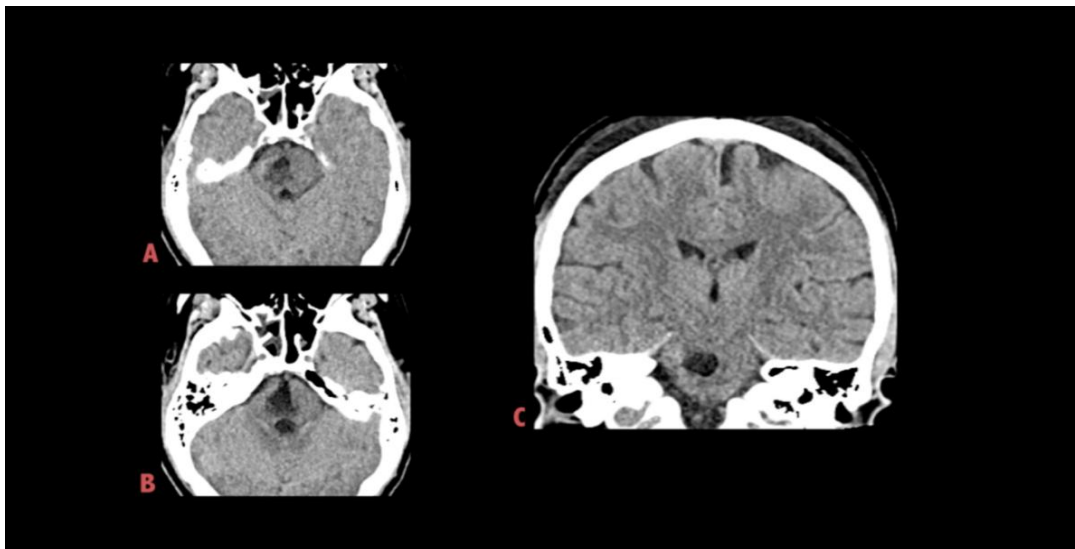


Fig. 36: Postoperative CT of brain stem cavernoma.

A & B: axial view, showing complete removal of the pontine cavernoma.

C: Coronal view.

No thermal or mechanical complications were recorded from the endoscope. 1 patient (33.3%) had a postoperative mild disturbance of balance, and 2 patients (66.6%) had postoperative hydrocephalus. 1 patient stayed in ICU for 20 days.

4.3.1.6. Fourth ventricle tumors

3 cases of the fourth ventricular tumor were operated in concorde position via median suboccipital approach. 2 patients were the first time to be operated and 1 patient had a recurrent pathology.

Inspection with the endoscope helped us to explore the fourth ventricle looking around the corners and inspecting areas that not seen by the initial view of the microscope. Moreover, it supported detection of residual tumor at the aqueduct or in the lateral recess allowing dissection and total removal of the tumor.

Complete removal of the lesion was confirmed in the follow-up MRI in 2 cases (66.6%) and a residual tumor was detected in 1 case (33.3%). The histopathological examination revealed:

- 1 case of medulloblastoma grade-IV,
- 1 case of pilocytic astrocytoma,
- 1 case of plexus papilloma grade-I.

No thermal or mechanical injuries were recorded from the endoscope.

Postoperative follow up showed:

- *1 case (33.3%) of rest tumor.
- *1 case (33.3%) postoperative hydrocephalus.

4.3.1.7. Foramen magnum tumors

2 cases of foramen magnum meningioma were operated in concorde position via median suboccipital approach and in supine position via retrosigmoid approach. All patients were first- time to undergo surgery.

Inspection with the endoscope provided us with the ability to look around the corners inspecting areas not seen by the initial view of the microscope, especially with the narrow surgical corridor.

Total removal of the lesion was confirmed in the follow-up MRI in 2 cases (100%). The histopathological examination in all cases revealed meningothelial meningioma grade-I.

No thermal or mechanical injury was recorded from the endoscope recorded.

4.3.2. Non-tumor group

4.3.2.1. Vascular lesions

The vascular lesions included total 6 patients:

(1 Patient) PICA Aneurysm,

(2 Patients) VA Aneurysm,

(3 Patients) BA Aneurysm.

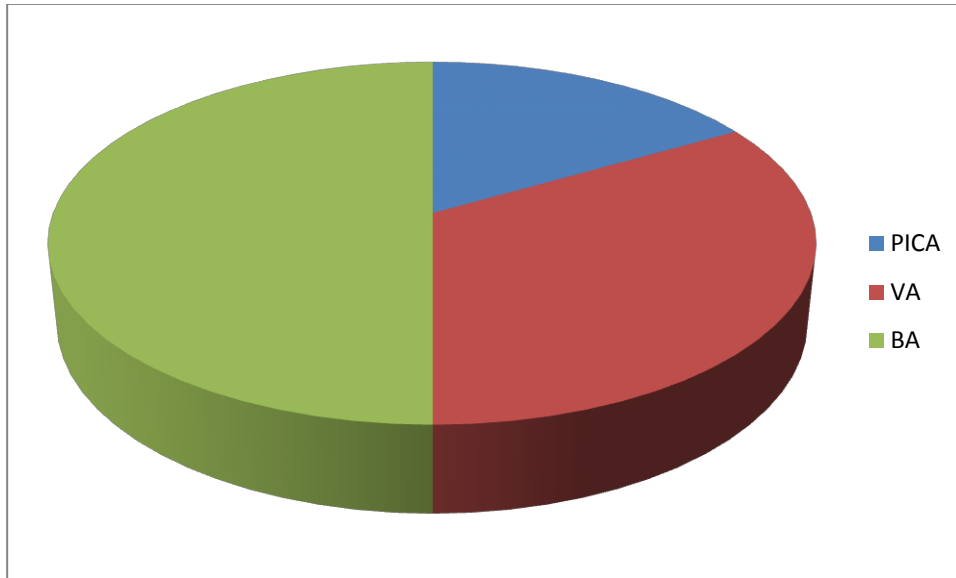


Fig. 37: Vascular group

2 patients were operated in concorde position via median suboccipital approach, 2 patients were operated in supine position via pterional approach, 1 patient was operated in barck pench position via subtemporal approach, and retrosegmoid approach in supine position was used for 1 patient.

Uncomplicated complete clipping of the aneurysms or deciding to do wrapping (in one case) was successfully achieved. The use of the angle-type rigid endoscope together with microscope increased the feasibility of a complete safe clipping procedure, with minimal risk of intraoperative complications as rupture or incomplete occlusion as well as postoperative complications due to vasospasm. Postoperative follow-up showed:

*1 case (14.2%) of hydrocephalus.

*1 case (14.2%) of disturbed balance

*1 case (14.2) of a hypodense lesion in the follow-up CT. This patient stayed for 14 days in our ward.

4.3.2.2. CSF fistula repair

1 patient was operated in supine position via retrosigmoid approach. The patient had a CSF fistula in left CPA after VS resection. Total uncomplicated occlusion of CSF fistula was successfully achieved.

4.3.2.3. Hemifacial spasm

MVD of the facial nerve was carried out in supine position via retrosigmoid approach for one patient with chronic facial spasm.

The 30-degree angular endoscope was used to identify the offending blood vessel in case of the HFS. Total recovery of the presenting symptoms was achieved immediately postoperatively with no intermittent residual convulsion. The patient had postoperative meningitis.

4.3.2.4. Trigeminal neuralgia

6 patients with trigeminal nerve pathology were operated in supine position via retrosigmoid approach for 5 patients and via pterional approach for 1 patient. The anatomical integrity of the trigeminal nerve was preserved in 100 % of patients.

The endoscope was very useful in visualization and identification of the offending blood vessel loop in 5 patients with trigeminal neuralgia. Teflon patch was inserted under the microscope and controlled with the endoscope. Postoperative outcome is classified into four categories:

- Immediate complete relief (4 cases),
- Delayed relief (2 cases),
- Failure (0 cases),
- Recurrence of neuralgia after one year (0 cases).

The endoscope has also facilitated a biopsy in one case of trigeminal ganglion inflammation.

In our present study, the anatomical integrity of the facial nerve was preserved in cases of VS, CPA epidermoid cyst, and HFS. Only one case of postoperative facial palsy needed a sural graft.

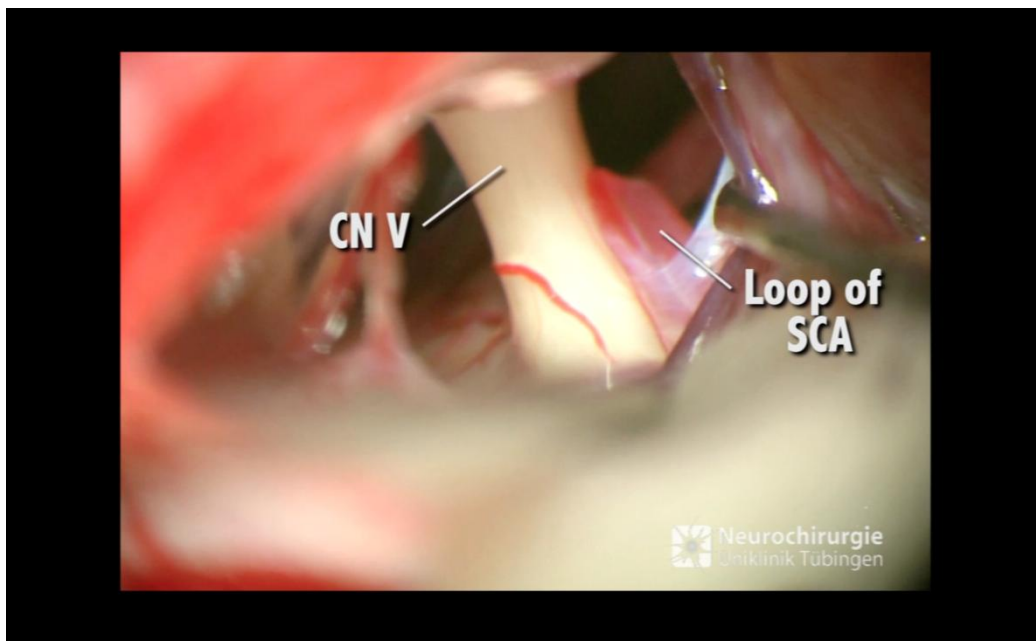


Fig. 38: Microscopic view: Loop of SCA compressing CN V.

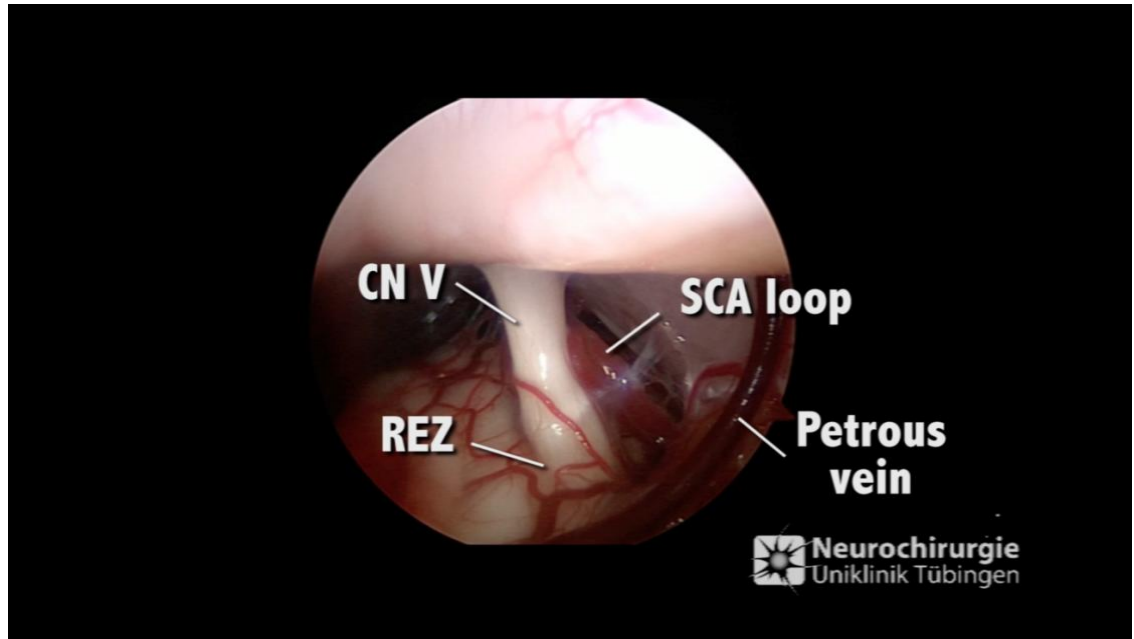


Fig. 39: Endoscopic view: Loop of SCA compressing CN V and exploration of the REZ.

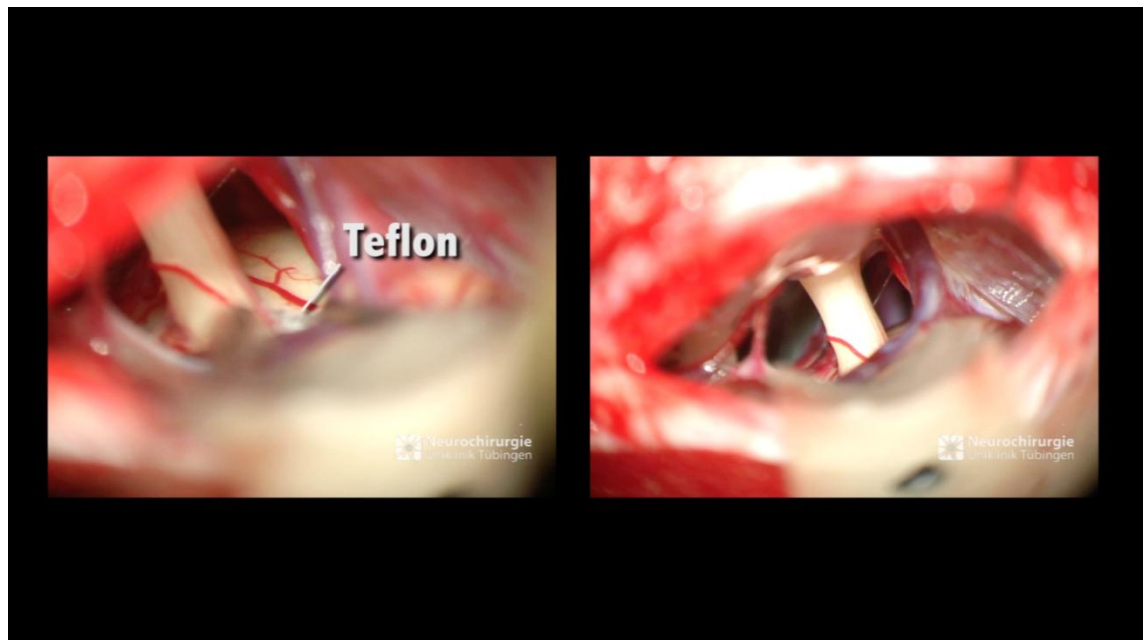

Fig. 40: Microscopic view: Teflon application.

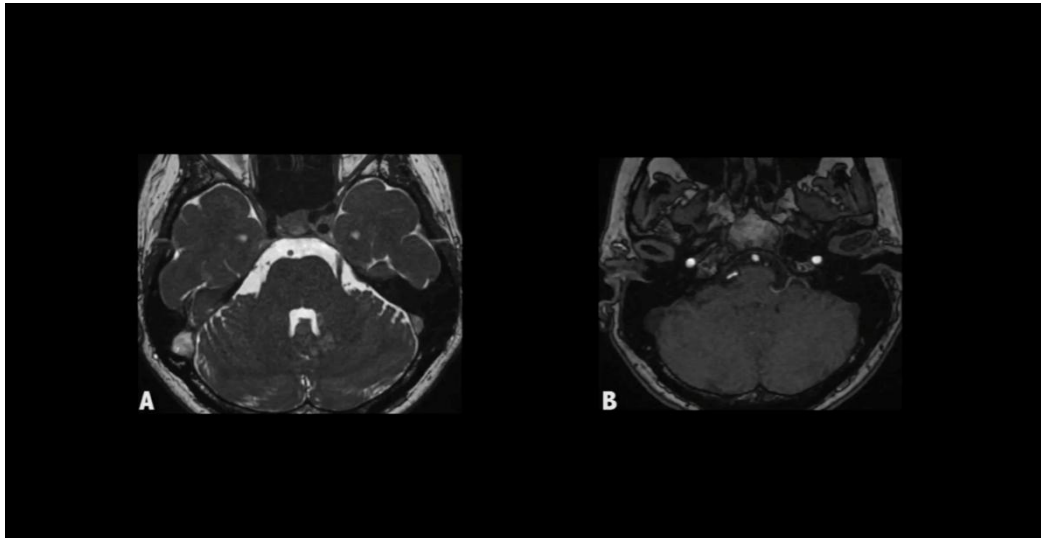


Fig. 41: Preoperative MRI of trigeminal neuralgia.

A: T2 axial view showing left CN V.

B: Time-of-Flight (TOF) MRI showing the compressing loop.

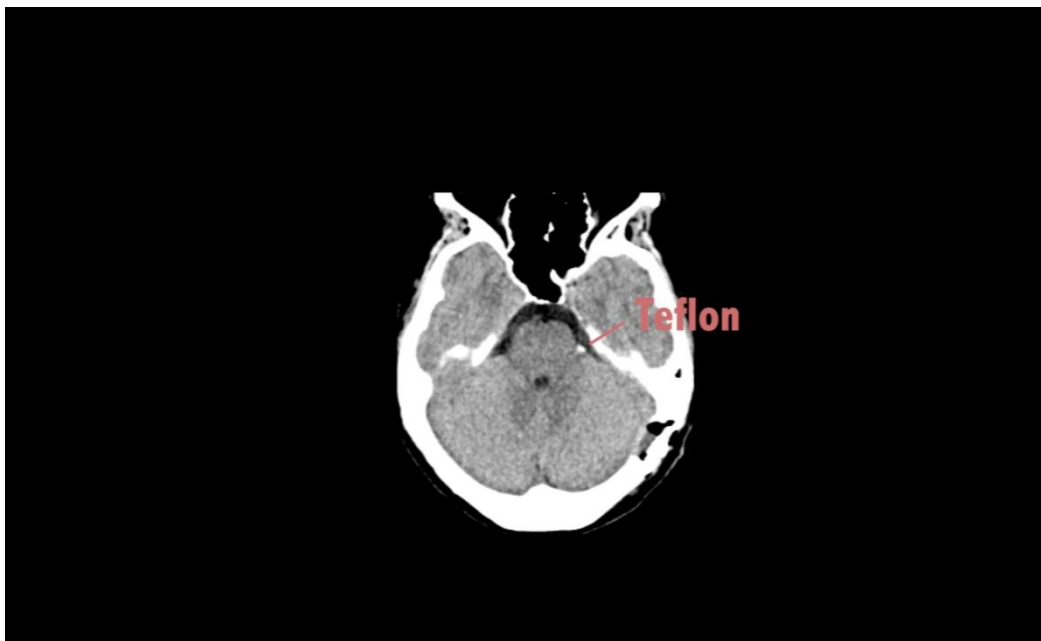

Fig. 42: Postoperative CT of trigeminal neuralgia.

4.4. Value of the endoscopic assisted procedure

The endoscope provided us with more information to evaluate the tumor and neurovascular relationship than what was available with the microscope alone. A 30-degree lens endoscope was more suitable to evaluate the most lateral part of the auditory canal. The only complication related to the endoscope was one case of mechanical injury to CN IV. No significant affection on the time of the operation as the average endoscopic procedure time was 20 minutes in our study. We believe that these 20 minutes are not extra time but necessary time to save more time could be wasted without obtaining ideal results.

No intraoperative hemorrhage in this study was recorded. There was no surgical mortality in this study. No cases of thermal injury.

5. Discussion

5.1. Surgical procedures and techniques

Before 1990, all operations of the CPA were performed under the microscopic visualization only (Culter et al. 2012). Hitotsumatsu et al. considered that the illumination might be weak during microsurgery due to a narrow surgical field. However, the endoscope can bring light inside the depth of the surgical field giving the surgeon a good panoramic view (especially with angled endoscopes) to differentiate precisely between the pathological and the normal anatomy (Hitotsumatsu et al. 2003).

O'Donoghue and O'Flynn in 1993 classified the CPA endoscopically into four levels including:

Level 1: CN V, VI, Meckel's cave, (SCA), and superior petrosal vein.

Level 2: CN VII, VIII, and AICA.

Level 3: CN IX, X, and PICA.

Level 4: CN XI, XII, lower medulla, and upper spinal cord. (O'Donoghue and O'Flynn 1993).

Endoscopic surgery as a minimally invasive procedure has many advantages in comparison with microsurgery such as increasing visualization without retraction, reducing surgical trauma, identification of neurovascular structures, and ensuring surgical success with less postoperative morbidity (Artz et al. 2007).

The endoscope provides the operator with superior intraoperative illumination and magnification of the surgical field in addition to the possibility of 'looking around the corners' which is one of the most significant advantages of the endoscope therefore, the endoscope facilitates more safe radical surgeries (Shahinain et al. 2004).

On the other hand, the endoscope has many disadvantages such as obscuring of the lenses by blood, lack of three-dimensionality (3D) vision, thermal injuries to the vital structures, and unavailability of special instruments designed for the endoscopy of CPA (Cappabianca et al. 2002).

From here originates the basic value of EAM which is to combine the advantages of both microsurgery and endoscopic surgery together (Hopf and Perneczky 1998). As EAM offers significant improvement in the illumination as well as the visualization of areas next to the central lesion (King et al. 2001).

The endoscope also provides the possibility to inspect the bony orifices without tissue removal or retraction allowing a less traumatic procedure (Mobbs and Tew 2001). Through simple maneuvering with the microscope and the endoscope, the surgeon can access and expose hidden regions (King et al. 2001).

Every surgical procedure can produce tissue damage. One of the best ways to reduce traumatization of the tissues is to avoid touching them and even better not to expose them. Decreasing the craniotomy size can reduce the risk of tissue injury (Charalampaki et al. 2005).

The introduction of the endoscope in neurosurgical procedures has significantly reduced the incidence of neurovascular injury in comparison to traditional neurosurgical techniques. It stated by Wilson more than 35 years ago, "the ideal exposure should be sufficient to do the job completely while preserving the integrity of healthy tissue as much as possible" (Fatemi et al. 2009).

It is important to be careful not to injury the neurovascular structures and keep in mind always that the angled endoscopes have a sharp front edge compared with a 0° endoscope, which prevents the surgeon to see the trajectory of the insertion behind the lens (Hori et al. 2006). That's why it is important to apply the endoscope under the operating microscope to inspect the position of the endoscope because the shaft of the endoscope can injury vital anatomical structures (Tatagiba et al. 1996b).

5.2. Outcome in various lesions

5.2.1. Cerebellopontine angle lesions

The most common tumor in CPA is VS, followed by meningioma, and epidermoid cysts (Izycka-Swieszewska et al. 2006). Non-tumorous pathologies are trigeminal neuralgia and HFS (Hitotsumatsu et al. 2003).

CPA lesions may present clinically with different neurological symptoms and signs such as cranial nerves dysfunction, cerebellar dysfunction, brainstem compression, raised intracranial pressure, and localized or non-localized headache. MRI is considered the radiological method of choice for the

diagnosis of CPA tumors. CT is more useful to evaluate the bony structures and to describe the precise relation of the tumor to IAC (Izycka-Swieszewska et al. 2006).

The surgical treatment of CPA lesions is aiming mainly to achieve total removal of the lesion preventing progressive neurological disability with maintaining the function of the regional cranial nerves as well as avoiding mortality and morbidity (Jarrahy et al. 2002). However, this could be difficult in some cases. That's why Samii et al. advised to do a subtotal microsurgical resection to keep the functional integrity of the cochlear nerve in the last hearing ear (Samii et al. 1997).

Approaching CPA is carried out nowadays with the assistance of a rigid endoscope to the microsurgical procedure. This technique has many advantages such as excellent visualization of the nervus intermedius, CN VII, CN VIII, adjacent vascular branches, and any remaining parts of the lesion. Moreover, the endoscope enhances the surgical maneuverability with actual 360° movement for visualization of the CPA structures and behind the corners with minimal retraction of the cerebellum (Charalampaki et al. 2005).

5.2.2. Vestibular schwannoma

In cases of VS, the surgical approaches require obtaining an excellent access to the CPA with maximal exposure of the IAC with attempting to maintain the functions of CN VII and VIII (Yong et al. 2008). The whole IAC up to its funds should be carefully inspected for tumor remnants or opened air cells (Pieper 2012).

King and Wackym reported that the value of angled endoscopes during EAM to treat VS is good exploration and visualization of the IAC as the endoscope provides superior visualization of residual tumor and opened air

cells, thus improving the outcome minimizing the complication rates (King and Wackym 1999).

Wackym et al. reported in 19 patients (28%) out of 68 patients there were exposed air cells, which were not identified or seen with the microscope during retrosigmoid approach but were visualized endoscopically (Wackym et al. 1999). Göksu et al. documented in a study that a percentage of 0 – 17.6% of tumor remnant after total microsurgical removal are detected by the endoscope (Göksu et al. 1999).

It is advised to leave about 3 millimeter (mm) of the bony canal intact at the fundus to avoid injury of the labyrinth. This incomplete exposure of the canal may lead to subtotal removal of the tumor with high recurrence rate (Tatagiba et al. 1996a).

Tatagiba et al. reported that the endoscope is an ideal assistant tool in cases of microsurgical treatment of VS to explore the whole IAC. With direct exploration of the IAC, the surgeon can achieve complete safe removal of Intra canalicular tumors under vision, direct control of the lateral Intra canalicular nerve portions, and the “blind” area of the fundus (Tatagiba et al. 1996a).

The endoscope is very useful during the step of opening of the IAC providing a close-up view of the drilled wall thus, enables improved identification of the posterior semicircular canal helping to maintain its function in the hearing (Shahinian and Ra 2011).

Samii et al. and others noted their experience and found the assistance of the endoscope was helpful in avoiding extensive drilling of the posterior portion of the internal acoustic meatus as well as preservation of hearing during VS surgery (Samii et al. 1997).

Hori et al. in a series of 32 patients of VS achieved full anatomical preservation of the facial nerve in 31 patients (Hori et al. 2006). Yuguang et al. in a series of 28 endoscopic assisted CPA surgeries reported that the recurrences rate was 0% (Yuguang et al. 2005).

We recorded in our study 2.5% recurrence rate of VS (in one patient only). Follow-up MRI was performed to exclude tumor recurrence at 3, 12, and 24 months postoperatively. Facial nerve function was assessed using the HB (House and Brackmann 1985).

Kabil et al. -in larger series with 1177 cases of EAM- found that the most common complications were CSF leakage, encountered in 3.6% cases (Kabil et al. 2005).

In the 1990s, only few teams have supported the use of the endoscope during the microsurgery of VS. Now, it is widely supported by many centers thanks to many advantages of the endoscope such as allowing safe radical surgeries, several clinical applications, smaller incisions, minimal postoperative pain, faster rehabilitation, better cosmetic results, shorter hospitalization as well as reducing mortality and morbidity rates (Tatagiba et al. 1996a).

We didn't record any cases of thermal injury during EAM in our study. The potential thermal injury resulted from the prolonged use of the endoscope close to neurovascular structures. It can be avoided by irrigation of the operation field through the irrigation sheath (Gerganov et al. 2010).

We document the great value of the endoscope in reducing cerebellar retraction and tissue traumatization to achieve safe totally remove of VS as it was also documented by Yuguang (Yuguang et al. 2005).

5.2.3. Epidermoid cyst of CPA

Epidermoid tumors are benign congenital lesions typically present between the third and fifth decades of life and account for 0.2-1.8 % of all intracranial tumors (Nagasawa et al. 2011).

The clinical picture of CPA epidermoid cyst is mainly due to the presence of adhesions as well as compression of adjacent neurovascular structures and brainstem. They tend to spread widely along the subarachnoid space and encompass adjacent important neurovascular structures (Nagasawa et al. 2011). Adherence to vital neurovascular structures can result from a chronic inflammatory reaction, while compression is due to the growth of the tumor (Yilmazlar et al. 2004).

Before the microsurgical era, the surgical mortality rate with epidermoid tumor ranged from 20-57 % (Caldarelli et al. 2004). This rate has been significantly decreased with the improvement of the microsurgical procedures. However, the morbidity rate of surgery is still relatively high (Samii et al. 1996b).

Obrador and Lopez-Zafra described that the epidermoid tumor is a “pearly tumor” with an irregular lobulated surface formed of thin capsule lined with epithelial cells containing keratin, water, and cholesterol from cell membrane degradation (Obrador and Lopez-Zafra 1969).

Evacuation of the cyst contents can be easily achieved because of its solid avascular nature. However, the capsule may be firmly adherent to the adjacent neurovascular structures or the brainstem making total removal a risky option (Schroeder et al. 2004).

Moreover, small parts of the tumor may extend into the narrowest deep spaces posterior and anterior to the nerves in the surrounding cisterns, which requires more retraction during surgery to reach these hidden parts. This

retraction may injury the neurovascular structures. In the classic retrosigmoidal approach, a larger bone window, as well as more retraction of the cerebellum, is required to allow direct view of the targeted neurovascular structures (Van Rompaey et al. 2013).

Safavi-Abbasi and his colleagues documented that one of the pitfalls of purely endoscopic removal of a CPA epidermoid tumors is that, the endoscope cannot see the instruments before they come in front of the lens which put the neurovascular structures at high risk of injury. This drawback can be avoided when the instruments are controlled by the microscope before reaching the front of the lens (Safavi-Abbasi et al. 2008).

Because of the nature and the location of the epidermoid, the endoscope has been applied to assist the microscope (De Divitiis et al. 2007). Tatagiba et al. documented that the EAM allows visualization of the hidden corners permitting total removal of any remnants that might be adherent to the vessels or the nerves which are responsible for the recurrence. This step is difficult to be achieved with the microscope alone. That's why the potential risk of recurrence with microsurgery is relatively high (Tatagiba et al. 2014).

Yuguang et al. found that the assistance of the endoscope to the operating microscope improves the rate of complete removal of epidermoid tumors in the CPA with reduction of the incidence of postoperative complications and recurrence rate. Although the microscope provided a satisfactory view of the posterior surface of the vestibulocochlear nerve, it was difficult with the microscope alone to see the REZ of CN VII from the brainstem and the entrance of the facial nerve into the porus of the internal auditory meatus. In contrast, the endoscope can provide excellent views of the medial side of CN VII and the vascular relationships anterior to them (Yuguang et al. 2005).

De Divitiis et al. reported a better visual control of the neurovascular structures without excessive retraction or enlarging the craniotomy size in a series of 8 patients with CPA epidermoid tumor treated with endoscopic assisted resection (De Divitiis et al. 2007).

5.2.4. Clival tumors

The complex anatomy of the petroclival region as well as the tendency of pathologies as meningiomas, trigeminal schwannomas, epidermoid cysts, chordomas, and chondrosarcomas to extend either supratentoriell or to the middle cranial fossa make the traditional surgical intervention a high risky procedure. However, multiple strategies and various approaches have been documented to expose this region with minimal complications; it still carries to some extent certain disadvantages. On the other hand, endoscopic assisted technique has been recently introduced as a minimally invasive technique to reduce the traditional approach-related morbidity, sparing surgical times, and improving the outcome (Tatagiba et al. 2015).

Chordomas are slow-growing malignant infiltrating bony tumors that arise from remnants of the notocord involving both ends of the axial skeleton and account for approximately 1% of intracranial tumors (Asano et al. 2003).

35%-40% of these pathologies occur in the skull base, where they commonly located at the clivus (Meyers et al. 1992). These tumors are locally aggressive with a destructive behavior which is responsible for the high rate of recurrence after surgical resection (Michele and Samuel 2003).

They are often not manifested clinically until late stages of the disease, because of the slow-growing features that's why they are manifested when they significantly enlarged (Jahangiri et al. 2013).

The patient presented with headache, diplopia secondary to CN VI paresis, and visual affection or sometimes loss of vision (Koshiyama et al. 1992). VII palsy or multiple lower cranial nerve palsies like dysphagia, hoarseness, and speech problems may occur. Brainstem compression can be seen in cases of large sized tumor (Menezes et al. 1997).

Chondrosarcoma is a rare tumor of the skull base. The prognosis is unfavorable because of the close relationship of the tumor to vital neurovascular structures, the large size of the tumor, and the difficulty to achieve complete resection. The established concept is to do incomplete uncomplicated resection (partial resection) is better than a harmful radical resection (Lohnstein et al. 2006).

We agree with Maier et al. that it is often not possible in the advanced tumor to do a complete resection. However, the goal of surgical treatment is to achieve maximal safe surgical resection with minimal surgical morbidity (Maier et al. 2006).

Endoscopic-assisted supra meatal extension (with an opening of the tentorium) of the retrosigmoid approach is standardized as a low morbid approach for the treatment of petroclival meningiomas, trigeminal schwannomas, and epidermoid cyst located in the posterior fossa and extending to the middle fossa over the extensive petrosectomies (Tatagiba et al. 2014).

We expect that the new advances in the tools of visualization and instruments will enable us to do a safe radical resection improving the prognosis of chordomas with the help of the modern advances in intraoperative navigation and radiotherapy.

5.2.5. Fourth ventricle tumors

Ependymomas are slow-growing malignant tumors which originate from the ependyma of the ventricles. They grow by both expansions into the ventricle and infiltration into the brain substance. The floor of the fourth ventricle is one of the most common sites of the ependymoma (Furie and Provenzale 1995).

Approaching the fourth ventricle for surgical management of intraventricular tumors requires a large suboccipital craniotomy or craniotomy with splitting of the cerebellar vermis in the midline or a trans-cerebellar approach. The potential hazards of these methods are the surgical damage to the midline structures with subsequent postoperative neurocognitive deficits, and `cerebellar mutism` or `posterior fossa syndrome` (Grill et al. 2004).

The fourth ventricle can be approached either microsurgically using the telovelar approach or endoscopically (Fries and Perneczky 1998). Although the microscope is a valuable tool in magnification and illumination, its field of vision is still limited and cannot view the structures which are not in its straight line of vision. However, the endoscope expands the field of view (magnification) and brings the viewing lens with light into the center of the operative field (illumination) (Tatagiba et al. 1996b).

Avoiding injury of the vermis or the cerebellar hemisphere to eliminate these postoperative complications was the primary concern in approaching the fourth ventricle. The telovelar approach enables a vermian-sparing access and thus, offers less traumatic maneuvers especially in pediatrics (Deshmukh et al. 2006).

The pathology could be to some extent estimated from the patient's age, symptoms, site, and radiological appearance of the lesion. Medulloblastoma and pilocytic astrocytoma are frequently seen in the 4th ventricle in pediatrics (Qian et al. 2012).

Recently, EAM techniques become more popular for approaching interaventricular tumors. In our study, we approached the fourth ventricle with EAM for lesions that invade the fourth ventricle. We found that EAM provides an excellent visualization, especially around corners allowing a less invasive and traumatic surgery with good prognosis. This method can be used safely for all types of tumors.

5.2.6. Foramen magnum tumors

Meningiomas are the most common benign tumor frequently seen in the region of the foramen magnum (Samii et al. 1996a). Foramen magnum meningiomas are strictly intradural. However, an associated extradural extension may be detected. Pure extradural meningiomas are very rare (Stein et al. 1963).

Foramen magnum meningiomas arise from arachnoid at the craniospinal junction. Extends craniocaudally from the lower third of the clivus to the upper margin of the body of C-2, anteroposteriorly extends from the anterior edge of the squamous occipital bone to the C-2 spinous process, and laterally from the top of the C-2 laminae to the jugular tubercle (Fine et al. 1999).

Foramen magnum meningiomas are located in close relation to vital neuromuscular structures such as lower cranial nerves, VA, and the neuroaxis. This location makes surgical management very challenging (Bruneau and George 2008).

The wide subarachnoid space at this region and the slow-growing rate hinders early detection of foramen magnum meningioma. That's why it is always late to discover these lesions (Boulton and Cusimano 2003).

It is more difficult with anteriorly located meningioma as well as cases of extradural extension of the tumor (George et al. 1997). Other factors which can affect the outcome of surgery are the absence of arachnoidal sheath and the firm adhesions in recurrent cases (Bassiouni et al. 2006).

Different surgical approaches are described to access this region. In 1990, Sen and Shekhar were the first to describe the extreme-lateral transcondylar approach (Sen and Sekhar 1990). The far lateral approach is described by Rhoton (Rhoton 2000b). Goel recommended the posterior midline approach for anterolaterally located lesions (Goel et al. 2001).

Schroeder et al. pointed -in a series of 46 patients with skull base meningiomas operated (23 via a retrosigmoid approach) in endoscopic assisted technique - that using the endoscope has minimized the bone drilling (Tatagiba et al. 2014).

With anteriorly located meningioma or meningioma without displacement of the neuromuscular structures, the surgical corridor is always narrow which makes the traditional microsurgery difficult without extensive bone drilling. In our study, the endoscope was applied to assist the microscope giving panoramic view of the tumor, checking any residual tumor, and to ensure hemostasis. Our results showed that endoscopic-assisted surgery for foramen magnum lesions is suitable, safe, and improves the outcome with little morbidity.

5.2.7. Trigeminal schwannoma

Smith has described trigeminal neuroma in 1849 (Bordi et al. 1989). It is also known as schwannoma or neurilemmoma, represents 0.1-0.4% of intracranial tumors and 1-8% of neuromas (Al-Mefty et al. 2002).

Yoshida et al. classified trigeminal schwannoma according to its location into:

- Type M: Tumors originate from the Gasser ganglion or its branches on the lateral wall of the cavernous sinus. Located in the middle cranial fossa.
- Type P: Tumors originate from the root of the CN V. located in the posterior fossa.
- Type E: Tumors originate from the extracranial portion of the CN V.
- Type MP: Dumbbell- shaped tumors. Located in both the middle and posterior cranial fossa equally.
- Type ME: Dumbbell-shaped tumors located in the middle fossa with the extracranial compartment.
- Type MPE: Tumors in the middle, posterior fossa, and in the extracranial compartment (Yoshida et al. 1999) (Al-Mefty et al. 2002).

The lesion can be approached by either suboccipital retrosigmoid approach to the posterior fossa or a combined approach in cases of the cavernous sinus invasion (Fries G and Perneczky A 1998).

EAM facilitates approaching trigeminal schwannoma offering safe total removal and considered as a minimally invasive technique with low associated morbidity. The endoscope as an assistant tool has a significant role in visualization and identification of the critical neuromuscular structures in the posterior fossa (Hopf and Perneczky 1998).

Lesions at the CPA and Meckel's cave could be metastases, lymphomas, bone tumors, or meningiomas and should be carefully preoperative differentiated (Al-Mefty et al. 2002).

Ebner et al. found that the retrosigmoid intradural suprameatal approach with the assistance of endoscope can access the medially located central skull base structures including the posterior part of the cavernous sinus and lesions extending from posterior fossa (Ebner et al. 2009).

5.2.8. Brainstem tumors

Cavernoma is a vascular malformation which displaces the nearby nervous tissue. Presented clinically with different symptoms like a focal neurologic deficit, headache, or seizure due to hemorrhage. Incidence is estimated by 0.4–0.5% in the general population (Del Curling et al. 1991). 20% of the intracranial cavernoma located within the brainstem, frequently seen within the pons because of its relatively large size (Gross et al. 2011).

The importance of brainstem cavernoma originated from the eloquence of the brain stem tissue as well as the high possibility of hemorrhage. Porter et al. reported that 97% of 100 patients with brainstem cavernoma had focal neurological deficits. However, most of the supratentorial cavernomas are discovered incidentally (Porter et al. 1999).

Brainstem cavernoma are characterized by higher rates of hemorrhage in comparison to other intracranial cavernomas. The incidence of bleeding by brain stem cavernoma ranged from 2.3%-8.7% compared with 1.6–3.1% for other cavernomas (Li et al. 2014). Moreover, the incidence of the rebleeding is estimated by 5%-35% per year (Steiger et al. 2006).

A microsurgical or endoscopic retrosigmoid approach can be performed to explore and resect the lateral pontine lesion. The endoscope plays a significant role in exploration and visualization of the lesion during this approach (Samii et al. 2000). The lesion could be approached through “safe entry zones” to avoid injury of the vital structures (de Divitiis et al. 2004).

Ebner et al. documented the advantages of EAM via retrosigmoid approach to access the ambient and interpeduncular cistern (Ebner et al. 2007).

We agree with Lang et al. that the future of the EAM dealing with lesions in brain stem will be promising. We are looking forward to more development and advancement of the instruments used with angled endoscope (Lang et al. 2012).

Brainstem cavernoma is one of the most challenging pathologies because of the importance of the adjacent nervous tissue and the high incidence of postoperative bleeding in cases of subtotal resection. On the other hand, gross total resection is achievable. Understanding the natural history of the cavernoma as a benign lesion, careful preoperative planning, and using proper intraoperative technique are important factors that encourage complete cure (Gross et al. 2013).

The remnant of the cavernous malformation after surgery is hazardous because it responsible for postoperative fatal hemorrhage. For this reason Bertalanffy et al. mentioned the value of complete resection of the cavernous malformations (Bertalanffy et al. 1991).

We documented the advantages of endoscopic-assisted surgery in overcoming the traditional difficulties in such cases like restricted operative field due to deep-seated lesion with a large cavity as well as the ability to keep the brain stem incision as small as possible during the procedure performing total removal of the lesion with a unique identification of any bleeding points. Although we had recorded a few number of cases, our study revealed that a safe total resection of brainstem lesions such as cavernomas is achievable with endoscopic- assisted technique under IOM.

5.2.9. Aneurysm of posterior circulation

Endoscopes are frequently used during tumor resections. The indications of using the endoscope during aneurysmal surgery are; when the aneurysm

conceals behind its parent artery or when the aneurysm dome obscures its parent artery.

Fisher et al. reported the first study on the assistance of fiberscope in aneurysmal microsurgery and they documented a noticeable improvement of the intraoperative visualization of the regional anatomy with a significant advantage to reduce the time for temporary clipping. However, the disadvantages of the fiberscope were poor image quality and difficulty to keep its position constant (Fischer and Mastafa 1994).

Thanks to the superior quality of pictures (higher magnification and illumination) with the rigid endoscope, it is introduced now instead of fiberscope to visualize the neck of the aneurysm, the parent artery, and the perforating branches (Kakizawa et al. 2003).

De Notaris et al. reported that the microscope provided satisfactory views of the posterior surface of the lower CNs and PCA (P2), while the endoscope offers excellent views of the medullary junction, exit of the lower CN, and all parts of PCA (P1, P2, and P3) (De Notaris et al. 2009).

That's why the use of the endoscope in conjunction with the microscope can enhance the visualization of the deep structures during EAM which has a significant advantage over the standard microsurgical exposure. Moreover, the technique enables the surgeon to use the microsurgical instruments in the operative field adjacent to the lens of the endoscope with alternating the utilization of the endoscope and the microscope to facilitate exposure of difficult regions and hidden corners (Tatagiba et al. 1996b).

We found that the endoscope is a very helpful tool before clipping and after clipping to confirm the correct position of the clip, performing total occlusion or to do the wrapping.

Tatagiba et al. have used the endoscope to achieve direct clipping of aneurysms of the posterior circulations and to inspect the branch vessels after the clipping. They reported the value of the endoscope was to look around “blind corners” seeing the structures that were not explored with the microscope (Tatagiba et al. 1996b).

Significant advantages are obtained especially in “difficult” aneurysmal surgeries like concealed aneurysms, giant aneurysms, and generally in “narrow corridors.” However, there are two limitations of the endoscope. The first is that the stereoscopic aneurysmal dissection under the endoscope is still not safe. The second one is technical as the lack of simultaneity between endoscopic and microscopic images.

Basilar bifurcation aneurysms are located deep in the brain. This location limits the visualization of the aneurysm regardless the orientation of the microscope, while with 0° angled endoscope excellent images of the PCA, BA, and perforating arteries were obtained to ensure that the clipping procedures was completed. Doppler US is used to detect the patency of the parent artery after total occlusion of the aneurysm.

5.2.10. Trigeminal neuralgia

Trigeminal neuralgia is a disorder manifested with severe episodes of lancinating pain along the distribution of CN V. Spontaneous or triggered attacks by eating or speaking can last for seconds up to a minute. Severe attacks are associated with sleep deprivation, severe malnutrition, and depression (Castro et al. 2008).

The leading cause of trigeminal neuralgia is a nerve-vessel conflict. Conservative treatment fails to achieve complete resolution of the complaint because of the resistance or drug intolerance. On the other hand, the surgical treatment (MVD) is considered the best efficient method to cure the symptoms.

There are variable modalities of ablative procedures like (radiosurgery, percutaneous radiofrequency lesioning, balloon compression, glycerol, and rhizolysis). MVD offers the ability to define the primary cause, thus provides a definitive cure preventing the long-term recurrence of symptoms. Ablative procedures fail to achieve permanent cure (Amador and Pollock 2008).

MVD is based on the separation of the irritating vessel from CN V via interposition of appropriate isolating material. Teflon is the most commonly used material (Lovely and Jannetta 1997). Other materials like muscle, fascia, gelfoam, Ivalon sponges, and cotton gauze could be utilized (Goya et al. 1990).

Kondo reported that an immediate postoperative success rate of 96% after MVD is achievable (Kondo 1997). Sun et al. reported that the incidence of recurrence varies from 3-30% (Sun et al. 1994).

Tatli et al. in large series of 4884 patients with MVD found that the initial pain relief ranged from 76.4%-98.2% and the recurrence rates ranged from 4%-38% (Talti et al. 2008). Barker et al. in series of 132 patients with recurrent symptoms found that the most common causes of recurrence are either veins or small arteries not seen in the first operation (Barker et al. 1996).

One of the most valuable advantages of the endoscope during MVD of trigeminal neuralgia is providing an excellent panoramic view with the ability to access the entire course of the trigeminal nerve from pons to Meckel's cave with minimal cerebellar retraction. On the other side, -with the microscopic view- the course of the trigeminal nerve is frequently hidden deep to the tributaries of the superior petrosal vein or the protrusions of the petrous bone (Jennings and O'Donoghue 1998).

We documented in our present study that the compressing vessel in cases of trigeminal neuralgia is located mainly near the brain stem, medial to the trigeminal nerve. It was very difficult to see the offending loop with the

microscope. This leads to incomplete decompression or as an alternative, the superior petrosal vein with some of its tributaries should be sacrificed to gain adequate exposure of the trigeminal nerve. Occlusion of these veins may cause some complications such as hemorrhage, cerebellar swelling, and venous infarction (King et al. 2001).

The angled endoscopes have overcome these problems by preserving the superior petrosal veins and their tributaries as well as reducing retraction. The assistance of the endoscope during MVD of the trigeminal nerve has shown significant improvement in the outcomes with reduction of the complications when compared with conventional microsurgery. Kabil et al. reported in a comparative study between the endoscopic and the microscopic MVD that the mortality rate was 0% for the endoscopic group and ranged 0-1.4% in the microscopic group (Kabil et al. 2005).

Rak et al. pointed out that large trigeminal veins which compress the trigeminal nerve at the 2 to 3 mm of trigeminal nerve near the brain stem, at the inferior or anterior surfaces of trigeminal nerve can be easily missed, if these areas are not carefully seen and explored. However, with the endoscopic-assisted technique the exploration of these regions can be successfully achieved (Rak et al. 2004).

Charalampaki and others documented that the angled endoscope can be placed in front of the pathology to detect the compression by the hidden part of small arteries and veins. This step can be done at ease because of the ability of the angled endoscopes to see around the corners and inside the cavities like Meckel's cave, which cannot be recognized by the straight view of the microscope (Charalampaki et al. 2008).

"Turning the corner" for the exploration of the CPA which is the most important step of the procedure could be managed with both endoscope and microscope to explore -in assisted technique- the area of the proximal third of

trigeminal nerve. The microscopic view cannot reach this region, although the microvascular conflict frequently occurs in this area. Many reports have documented the better outcome with the aid of endoscope over the microscope which supports that the endoscope-assisted technique seems to be a promising technique (Tatagiba et al. 2014).

Teo and others documented that during endoscopic assisted MVD of trigeminal neuralgia a gentle retraction of the cerebellum, release of CSF from the basal cisterns, and lysis of the arachnoid bands were the standard in all cases (Teo et al. 2006).

De Notaris and his colleges reported that the microscope provided a satisfactory view of the posterior surface of the trigeminal nerve but adding the endoscope can provide excellent views of the trigeminal nerve's junction with the pons and its entrance into the porus of Meckel's cave. Moreover, advancing the endoscope deeply between the tentorium and CN V to assess the lateral aspect of the interpeduncular cistern thus, CNIII, IV, proximal SCA, PCA, the BA, posterior communicating arteries, and the higher clival region could be exposed with minimal retraction (De Notaris et al. 2009).

Matching with the results of other previous studies, we can standardize the value of endoscope as an assisting tool during MVD thanks to its excellent visualization and ability to detect the offending blood vessel with minimal retraction of the cerebellum

5.2.11. Hemifacial spasm

We report that the efficacy of endoscope in MVD for HFS originates mainly from the ability of the endoscope to expose the REZ of the facial nerve. This part is usually hidden laterally by the CN VIII or the flocculus. That's why it is not seen with the microscope. Eby et al. noted that the endoscope can

provide excellent panoramic views of the CPA and REZ of Cn VII, thus allowing real identification of any vascular compression (Eby et al. 2001).

Janetta was the first to perform MVD for HFS, and he documented that - because of the protrusion of the flocculus or choroid plexus below the facial nerve - it will be difficult to see the arterial loop which compresses a part of the facial nerve adjacent to the brainstem (Jannetta et al. 1977).

Magnan et al. reported that there is additional 72% accuracy in MVD of CN VII with the assistance of the endoscope in cases of HFS (Magnan et al. 1993). In other series Cheng et al. found in 32 patients whom underwent endoscopic assisted MVD for HFS that the procedure was successful in 97% of the patients (Miyazaki et al. 2005).

Badr-El-Dine et al. reported in a series of 80 patients of HFS followed-up for at least one year, the success rate was (96.25%) and the failure rate was 3.75% without significant postoperative complications. Postoperative complications were 3 patients (3.75%) with delayed facial palsy, and 2 patients (2.5%) with postoperative CSF leak treated surgically. The role of the endoscope in MVD for HFS was great in identifying the site of the compression in all cases and confirming the position of the Teflon to improve the postoperative outcome (Badr-El-Dine et al. 2002).

In other series, Cheng et al. reported that the success rate was 96.9% and improved in 3.1% without failure or recurrence. Postoperative complications were recorded in 2 patients. One patient (3.1%) experienced delayed facial palsy on the 7th day postoperative and recovered 2 months later. One patient (3.1%) with postoperative hearing affection. Cheng concluded that the endoscope can accurately identify the nerve-vessel conflicts and offers a better evaluation of the completeness of the decompression. Endoscopes as an adjunctive imaging modality to the microscope can confirm nerve-vessel

conflicts, can provide minimal retraction, and can explore hidden regions that escaped from the microscopic view (Cheng et al. 2008).

We not only agree with previous studies but also to confirm that there were no added facial or auditory deficits in our patients whom treated with EAM for trigeminal neuralgia and HFS.

In our present study, the time of working with endoscope ranged from 7 to 35 minutes. This time is affected by many factors such as the size, the extension, and the location of the lesion. However, Yuguang et al. mentioned that the endoscopic procedures added an average time of 15 to 30 minutes to the duration of surgery during endoscopic assisted MVD or large VS (Yuguang et al. 2005).

The goal of advancements in endoscopic technology is to create high-quality endoscopes with few disadvantages. Advancements inform of designing irrigation sheaths for cleaning the lenses during working inside the deep field, different lengths, as well as small working channel diameters with variably angled views, and special holders fixing the endoscope will give the endoscope the chance to be the most valuable tool with its full panoramic, multi-angled view in dealing with deep-seated lesions (Broggi et al. 2013).

5.3. The future of endoscopic-assisted technique

As we are looking forward to more advancement, more development, and more efficiency of this technique, we would like to address our vision for the future of this safe method answering the question, how could we advance this technique in the future?

Thinking in two different directions will accelerate the development of this technique allowing us to get use of the advantages of both endoscope and microscope. First of all, the surgical instruments; we are looking forward to an

exclusive design for the microsurgical instruments such as scissors, dissectors, bipolar, and forceps. Small size, variable length, and more angulations are our today's demands to facilitate safe dealing with any pathology in the hidden corners.

Regarding the microscope and the endoscope we have a vision, summarized in the possibility of integrating the advantages of both tools together in one device. Giving us the best visual field without any of the disadvantages of each tool when used separately, keeping the magnification and illumination functions of the microscope in addition to the most amazing function of the endoscope to look around the corners and exploring the hidden areas.

We believe that the new (H-Microscope 1) can make a new revolution in the field of challenging distant regions in skull base surgery giving us the ability to do complex operations exploring the invisible corners through a minimally invasive technique with maximum magnification, visualization, and safety.

One of the most significant advantages of the new microscope is safety, as it allows us to introduce the endoscope under complete control of the microscope seeing clearly what is behind the lens of the endoscope (the blind view of the endoscope) all through the procedure.

A modification of the microscope can be done by joining the sheath of the endoscope connected with its light source and its camera to the microscope just behind the surgical lens of the microscope. In a vertically right to oblique angled track runs perpendicular to another horizontally tract 360° around the surgical lens, through which the sheath of the endoscope will move up or down, anterior or posterior, and left or right around the lens of the microscope to reach the hidden region under the vision of the microscope. Movement of the endoscope in these tracks could be controlled through a fine motor. The

surgeon can adjust these movements through the hand of the microscope. The movement of the endoscope could be maneuvered by the basic movement of the microscope itself.

Another design could be suggested via connecting the endoscopic sheath externally to the body of the microscope by a freely mobile arm which can move in all directions through 3 joints (up-down joint), (right-left joint), and (anterior- posterior joint) allowing the endoscope to move in the horizontal track around the lens. This arm can be adjusted manually or automatically.

Moreover, it could be navigated by the brain lab in an automated fashion which will allow the precise advancement of the sheath with maximum safety. The sheath will be fixed into the field without the need of any additional hands. The lens angulation could be automatically adjusted and changed (0, 30, 45, 70)°.

How could we receive the images? The output is considered the difficult part in the issue, but we can suggest more than a method receive the images from both microscope and endoscope simultaneously.

One method could be from an external HD 3D screen. The other method could be through the microscope eyepieces itself and for this method we would need an intra-microscopic slide like the screen which could divide into two sections upper for the endoscopic view and lower Part of the microscopic view.

We would like to suggest the TM (Tatagiba-Mourad) classification of EAM based on the complexity of the procedure.

-TM0:Microsurgery only.

-TM1:Microsurgery then endoscopic inspection.

-TM2:Microsurgery then endoscopic inspection, then microsurgery.

-TM3:Microsurgery then endoscopic inspection then working with the endoscope without microscopic guidance.

*TM1+,TM2+,TM3+: Using the endoscope under microscopic guidance.

-TM4:Microsurgery + working with endoscope under microscopic guidance + (IOM / iMRI/ Navigator/ US).

6. Conclusions

It is critical to keep in mind that the necessary requirements to achieve” safe surgery “are the Vision and the Orientation. Good exposure, superior illumination in depth, better field magnification and the ability to explore the hidden corners and behind structures must be fulfilled to get the ideal vision.

Despite of the great value of the microscope in illumination and magnification of the regional anatomy in the microsurgical procedures in the field of skull base surgery, it still stands handicapped to meet the demand of seeking a “perfect visual tool” especially with complex posterior skull base lesions. Meanwhile, searching for an alternative or adjuvant visual tool was a must. As a visual tool, the microscope alone can't give what it cannot do.

Although the endoscope as a visual tool had solved many of the disadvantages of the microscope, it still can see only from its tip with the lack of backward vision which makes it risky to move the endoscope in the operative field.

From here came the idea to combine the characteristics of both tools in one procedure to complement each other through the application of the endoscope into the field under direct vision of microscope “endoscope-assisted technique “to obtain the perfect `Vision and Orientation` of all surgical field even the field behind the tip of the endoscope as well as the hidden corners and behind the structures.

Regarding this issue, we would like to address the advantages of using the endoscope as an assisted tool in posterior skull base microsurgery.

I- Visual Improvement of:

- Bony structures as IAC, Pori of Meckel's cave, and the basal foramina
- Opened air cells
- Extensions, borders and residual tumor
- Tumor capsule with any adhesions to nearby neurovascular structures
- Junction of nerves with the brainstem.
- Vascular segments anterior to the nerves (vascular nerve conflict)
- Dom, neck of an aneurysm, parent artery, and branches
- Bleeding points especially in deep regions
- Foramen magnum lesions in cases with narrow surgical corridor
- Corners of the fourth ventricle

II- Minimizing of:

- Skin incision
- Craniotomy size
- CSF drainage
- Retraction of cerebellum
- Traction on the neurovascular bundle
- Brain stem incision and consequent damage
- Injury of the labyrinth and deep veins
- Cerebellar injury
- Drilling of the bone
- Risk of postoperative bleeding
- Postoperative CSF leak
- Incidence of intraoperative aneurysmal rupture
- Time of operation
- Postoperative pain
- Mortality
- Morbidity

- Hospital stay
- Rehabilitation time
- Incidence of recurrence

III- Preservation of:

- Facial function
- Hearing function

VI- Confirming of:

- Ideal biopsy location
- Occlusion of fistula
- Correct clipping aneurysm
- Completeness of tumor removal
- Excellent position of the Teflon patch

We recommend EAM as a safe procedure to deal with different situations in which the microscopic view alone failed to provide us with the complete image to make a right final decision.

We expect more development and advances of endoscopic instruments which will cause the endoscope is the perfect tool assisting the microscope.

Reference List

Al-Mefty O, Ayoubi S, Gaber E (2002) Trigeminal schwannomas: removal of dumbbell-shaped tumors through the expanded Meckel cave and outcomes of cranial nerve function. *J Neurosurg* 96: 453-463.

Amador N, Pollock BE (2008) Repeat posterior fossa exploration for patients with persistent or recurrent idiopathic trigeminal neuralgia. *J Neurosurg* 108: 916-920.

Apuzzo ML, Heifetz MD, Weiss MH, Kurze T (1977) Neurosurgical endoscopy using the side-viewing telescope. *J Neurosurg* 46: 398–400.

Artz GJ, Hux FJ, Larouere MJ, Bojrab DI, Babu S, Pieper DR (2008) Endoscopic vascular decompression. *Otol Neurotol* 29: 995-1000.

Asano S, Kawahara N, Kirino T (2003) Intradural spinal seeding of a clival chordoma. *Acta Neurochir (Wien)* 145: 599-603.

Badr-El-Dine M, El-Garem HF, Talaat AM, Magnan J (2002) Endoscopically assisted minimally invasive microvascular decompression of hemifacial spasm. *Otol Neurotol* 23: 122-128.

Barker FG, Jannetta PJ, Bissonette DJ, Larkins MV, Jho HD (1996) The long-term outcome of microvascular decompression for trigeminal neuralgia. *N Engl J Med* 334: 1077-1083.

Bassiouni H, Ntoukas V, Asgari S, Sandalcioglu EI, Stolke D, Seifert V (2006) Foramen magnum meningiomas: Clinical outcome after microsurgical resection via a posterolateral suboccipital retrocondylar approach. *Neurosurgery* 59: 1177–1185.

Bertalanffy H, Gilsbach JM, Eggert HR, Seeger W (1991) Microsurgery of deep-seated cavernous angiomas: report of 26 cases. *Acta Neurochir (Wien)* 108: 91–109.

Bordi L, Compton J, Symon L (1989) Trigeminal neuroma. A report of eleven cases. *Surg Neurol* 31: 272-276.

Boulton MR, Cusimano MD (2003) Foramen magnum meningiomas: Concepts, classifications, and nuances. *Neurosurg Focus* 14: e10.

Broggi M, Acerbi F, Ferroli P, Tringali G, Schiariti M, Broggi G (2013) Microvascular decompression for neurovascular conflicts in the cerebellopontine angle: which role for endoscopy? *Acta Neurochir (Wien)* 155: 1709–1716.

Bruneau M, George B (2008) Foramen magnum meningiomas: Detailed surgical approaches and technical aspects at Lariboisiere Hospital and review of the literature. *Neurosurg Rev* 31: 19–32.

Bush RB, Leonhardt H, Bush IV, Landes RR (1974) Dr. Bozzini's Lichtleiter. A translation of his original article (1806). *Urology* 3: 119–123.

Caldarelli M, Massimi L, Kondageski C, Di Rocco C (2004) Intracranial midline dermoid and epidermoid cysts in children. *J Neurosurg* 100: 473–480.

Cappabianca P, Cavallo L M, Esposito F, de Divitiis E, Tschabitscher M (2002) Endoscopic examination of the cerebellar pontine angle. *Clin Neurol Neurosurg* 104: 387-391.

Castro AR, Siqueira SR, Perissinotti DM, Siqueira JT (2008) Psychological evaluation and cope with trigeminal neuralgia and temporomandibular disorder. *Arq Neuropsiquiatr* 66: 716-719.

Charalampaki P, Filippi R, Welschehold S, Conrad J, Perneczky A (2005) Tumors of the lateral and third ventricle: removal under endoscope-assisted keyhole conditions. *Neurosurgery* 57: 302–311.

Charalampaki P, Kafadar AM, Grunert P, Ayyad A, Perneczky A (2008) Vascular decompression of trigeminal and facial nerves in the posterior fossa under endoscope-assisted keyhole conditions. *Skull Base* 18: 117-128.

Cheng WY, Chao SC, Shen CC (2008) Endoscopic microvascular decompression of the hemifacial spasm. *Surg Neurol* 70: 40-46.

Cutler AR, Kaloostian SW, Ishiyama A, Frazee JG (2012) Two-handed endoscopic-directed vestibular nerve sectioning: case series and review of the literature. *J Neurosurg* 117: 507–513.

Daniel RK (1979) Microsurgery: through the looking glass. *N Engl J Med* 300: 1251-1257.

de Divitiis O, Cavallo LM, Dal Fabbro M, Elefante A, Cappabianca P (2007) Freehand dynamic endoscopic resection of an epidermoid tumor of the cerebellopontine angle: technical case report. *Neurosurgery* 61: 239–240.

de Divitiis O, Conti A, Angileri FF, Cardali S, La Torre D, Tschabitscher M (2004) Endoscopic transoral-transclival approach to the brainstem and surrounding cisternal space: Anatomic study. *Neurosurgery* 54:1 25–130.

De Notaris M, Cavallo LM, Prats-Galino A, Esposito I, Benet A, Poblete J, Valente V, Gonzalez JB, Ferrer E, Cappabianca P (2009) Endoscopic endonasal transclival approach and retrosigmoid approach to the clival and petroclival regions. *Neurosurgery* 65: 42-50.

Del Curling O Jr, Kelly DL Jr, Elster AD, Craven TE (1991) An analysis of the natural history of cavernous angiomas. *J Neurosurg* 75: 702–708.

Deshmukh V, Figueiredo E, Deshmukh P, Crawford NR, Preul MC, Spetzler RF (2006) Quantification and comparison of telovelar and transvermian approaches to the fourth ventricle. *Neurosurgery* 58: 202–206.

Ebner FH, Koerbel A, Kirschniak A, Roser F, Kaminsky J, Tatagiba M (2007) Endoscope-assisted retrosigmoid intradural suprameatal approach to the middle fossa: Anatomical and surgical considerations. *Eur J Surg Oncol* 33: 109–113.

Ebner FH, Koerbel A, Roser F, Hirt B, Tatagiba M (2009) Microsurgical and endoscopic anatomy of the retrosigmoid intradural suprameatal approach to

lesions extending from the posterior fossa to the central skull base. *Skull Base* 19: 319-323.

Eby JB, Cha ST, Shahinian HK (2001) Fully endoscopic vascular decompression of the facial nerve for hemifacial spasm. *Skull Base* 11: 189–197.

Fanouso AA, Couldwell WT (2012) Transnasal excerebration surgery in ancient Egypt. *J Neurosurg* 116: 743–748.

Fatemi N, Dusick JR, de Paiva Neto MA, Malkasian D, Kelly DF (2009) Endonasal versus supraorbital keyhole removal of craniopharyngiomas and tuberculum sellae meningiomas. *Neurosurgery* 64: 269–284.

Fine AD, Cardoso A, Rhoton AL Jr (1999) Microsurgical anatomy of the extracranial-extradural origin of the posterior inferior cerebellar artery. *J Neurosurg* 91: 645-652.

Fischer J, Mastafa H (1994) Endoscopic-guided clipping of cerebral aneurysms. *Br J Neurosurg* 8: 559-565.

Fries G, Perneczky A (1998) Endoscope-assisted brain surgery. Part 2: analysis of 380 procedures. *Neurosurgery* 42: 226-231.

Furie DM, Provenzale JM (1995) Supratentorial ependymomas, and subependymomas: CT and MR appearance. *J Comput Assist Tomogr* 19: 518-526.

George B, Lot G, Boissonnet H (1997) Meningioma of the foramen magnum: A series of 40 cases. *Surg Neurol* 47: 371–379.

Gerganov VM, Giordano M, Herold C, Samii A, Samii M (2010) An electrophysiological study on the safety of the endoscope-assisted microsurgical removal of vestibular schwannomas. *Eur J Surg Oncol* 36: 422–427.

Goel A, Muzumdar D, Desai K (2001) Surgery on anterior foramen magnum meningiomas using conventional posterior suboccipital approach: A report on an experience with 17 cases. *Neurosurgery* 49: 102–106.

Göksu N, Bayazit Y, Kemaloglu Y (1999) Endoscopy of the posterior fossa and endoscopic dissection of acoustic neuroma. *Neurosurg Focus* 15: 6-15.

Goya T, Wakisaka S, Kinoshita K (1990) Microvascular decompression for trigeminal neuralgia with special reference to delayed recurrence. *Neurol Med Chir (Tokyo)* 30: 462-467.

Grant JA (1996) Victor Darwin Lespinasse: a biographical sketch. *Neurosurgery* 39: 1232–1233.

Grill J, Viguier D, Kieffer V, Bulteau C, Sainte-Rose C, Hartmann O, Kalifa C, Dellatolas G (2004) Critical risk factors for intellectual impairment in children with posterior fossa tumors: the role of cerebellar damage. *J Neurosurg* 101: 152–158.

Gross BA, Batjer HH, Awad IA, Bendok BR, Du R (2013) Brainstem Cavernous Malformations: 1390 Surgical Cases from the Literature. *World Neurosurg* 80: 89–93.

Gross BA, Lin N, Du R, Day AL (2011) The natural history of intracranial cavernous malformations. *Neurosurg Focus* 30: E24.

Healy JF, Hesselink JR, 2006, Brainstem, cranial nerves, and cerebellum, 1138-1180, *Clinical Magnetic Resonance Imaging*, 3rd edition, Saunders-Elsevier, Philadelphia .

Hitotsumatsu T, Matsushima T, Inoue T (2003) Microvascular decompression for treatment of trigeminal neuralgia, hemifacial spasm, and glossopharyngeal neuralgia. three surgical approach variations: technical note. *Neurosurgery* 53: 1436-1441.

Hopf NJ, Perneczky A (1998) Endoscopic neurosurgery and endoscope-assisted microneurosurgery for the treatment of intracranial cysts. *Neurosurgery* 43: 1130-1136.

Hori T, Okada Y, Maruyama T, Chernov M, Attia W (2006) Endoscope-controlled removal of intrameatal vestibular schwannomas. *Minim Invasive Neurosurg* 49: 25–29.

House JW, Brackmann DE (1985) Facial nerve grading system. *Otolaryngol Head Neck Surg* 93: 146–147.

Izycka-Swieszewska E, Szurowska E, Kloc W, Rzepko R, Dubaniewicz-Wybieralska M, Skorek A, Drożyńska E, Stempniewicz M (2006) Cerebellopontine angle tumours: radiologic-pathologic correlation and diagnostic difficulties. *Folia Neuropathol* 44: 274-281.

Jahangiri A, Jian B, Miller L, El-Sayed IH, Aghi MK (2013) Skull base chordomas clinical features, prognostic factors, and therapeutics. *Neurosurg Clin N Am* 24: 79-88.

Jannetta PJ, Abbasy M, Maroon JC, Ramos FM, Albin MS (1977) Etiology and definitive microsurgical treatment of hemifacial spasm. Operative techniques and results in 47 patients. *J Neurosurg* 47: 321-328.

Jarrahay R, Eby J B, Shahinian HK (2002) A new powered endoscope holding arm for endoscopic surgery of the cranial base. *Minim Invasive Neurosurg* 45: 189-192.

Jennings CR, O'Donoghue GM (1998) Posterior fossa endoscopy. *J Laryngol Otol* 112: 227-229.

Kabil MS, Eby JB, Shahinian HK (2005) Endoscopic vascular decompression versus microvascular decompression of the trigeminal nerve. *Minim Invas Neurosurg* 48: 207-212.

Kakizawa Y, Hongo K, Takasawa H, Miyairi Y, Sato A, Tanaka Y, Kobayashi S (2003) “Real” three-dimensional constructive interference in steady-state

imaging to discern microneurosurgical anatomy. Technical note. *J Neurosurg* 98: 625–630.

Karasu A, Cansever T, Batay F, Sabanci PA, Al-Mefty O (2009) The microsurgical anatomy of the hypoglossal canal. *Surg Radiol Anat* 31: 363-367.

King WA, Wackym PA (1999) Endoscope-assisted surgery for acoustic neuromas (vestibular schwannomas): early experience using the rigid Hopkins telescope. *Neurosurgery* 44: 1095-1100.

King WA, Wackym PA, Sen C, Meyer G, Shiao J, Deutsch H (2001) Adjunctive use of endoscopy during posterior fossa surgery to treat cranial neuropathies. *Neurosurgery* 49: 108-115.

Kondo A (1997) Follow-up results of microvascular decompression in trigeminal neuralgia and hemifacial spasm. *Neurosurgery* 40: 46-51.

Koshiyama H, Sakamoto M, Fujiwara K, Kim YC, Teraura T, Koh T (1992) Chondroid chordoma presenting with hypopituitarism. *Intern Med* 31: 1366-1369.

Kriss TC, Kriss VM (1998) History of the operating microscope: from magnifying glass to microneurosurgery. *Neurosurgery* 42: 899–907.

Laine FJ, Nadel L, Braun IF (1990) CT and MR imaging of the central skull base. Part 2. Pathologic spectrum. *Radiographics* 10: 797–821.

Lang SS, Chen HI, Lee JY (2012) Endoscopic Microvascular Decompression: A Stepwise Operative Technique. *ORL J Otorhinolaryngol Relay Spec* 74: 293–298.

Leek FF (1969) The problem of brain removal during embalming by the ancient Egyptians. *J Egypt Archaeol* 55: 112–116.

Li D, Hao SY, Jia GJ, Wu Z, Zhang LW, Zhang JT (2014) Hemorrhage risks and functional outcomes of untreated brainstem cavernous malformations. *J Neurosurg* 121: 32–41.

Linder TE, Simmen D, Stool SE (1997) Revolutionary inventions in the 20th century. The history of endoscopy. *Arch Otolaryngol Head Neck Surg* 123: 1161–1163.

Liu JK, Das K, Weiss MH, Laws ER Jr, Couldwell WT (2001) The history and evolution of transsphenoidal surgery. *J Neurosurg* 95: 1083–1096.

Lohnstein PU, Schipper J, Tatagiba M, Gellrich NC, Berlis A, Maier W (2006) Skull base chondrosarcoma. An interdisciplinary challenge. *HNO* 54: 287-293.

Lovely TJ, Jannetta PJ (1997) Microvascular decompression for trigeminal neuralgia. Surgical technique and long-term results. *Neurosurg Clin N Am* 8: 11-29.

Magnan J, Chays A, Caces F, Lepetre C, Cohen JM, Belus JF, Bruzzo M (1993) Contribution of endoscopy of the cerebellopontine angle by retrosigmoid approach. Neuroma and vasculo-nervous compression. *Ann Otolaryngol Chir Cervicofac* 110: 259-265.

Maier W, Lohnstein PU, Rosahl SK, Tatagiba M, Schipper J (2006) Multidisciplinary management of skull base and craniocervical chordoma. *Laryngorhinootologie* 85: 272-278.

Menezes AH, Gantz BJ, Traynelis VC, McCulloch TM (1997) Cranial base chordomas. *Clin Neurosurg* 44: 491-509.

Meyers SP, Hirsch WL, Curtin HD, Barnes L, Sekhar LN, Sen C (1992) Chordomas of the skull base: MR features. *AJNR Am J Neuroradiol* 13: 1627-1636.

Michele SM, Samuel CL (2003) Chordomas of the skull base: manifestations and management. *Curr Opin Otolaryngol Head Neck Surg* 11: 324-327.

Miyazaki H, Deveze A, Magnan J (2005) Neuro-otologic Surgery through Minimally Invasive Retrosigmoid Approach: Endoscope Assisted Microvascular Decompression, Vestibular Neurotomy, and Tumor removal. *Laryngoscope* 115: 1612-1617.

Mobbs R, Teo C (2001) Endoscopic assisted posterior fossa decompression. *J Clin Neurosci* 8: 343-344.

Mudry A (2000) The history of the microscope for use in ear surgery. *Am J Otol* 21: 877-886.

Nagasawa D, Yew A, Safaee M, Fong B, Gopen Q, Parsa AT, Yang I (2011) Clinical characteristics and diagnostic imaging of epidermoid tumors. *J Clin Neurosci* 18: 1158–1162.

Obrador S, Lopez-Zafra JJ (1969) Clinical features of the epidermoids of the basal cisterns of the brain. *J Neurol Neurosurg Psychiatry* 32: 450–454.

O'Donoghue GM, O'Flynn P (1993) Endoscopic anatomy of the cerebellopontine angle. *Am J Otol* 14: 122-125.

Pernecky A, Fries G (1998) Endoscope-assisted brain surgery: part1 evolution, basic concept, and current technique. *Neurosurgery* 42: 219–224.

Pieper DR (2012) The endoscopic approach to vestibular schwannomas and posterolateral skull base pathology. *Otolaryngol Clin North Am* 45: 439–454.

Pirris SM, Pollack IF, Snyderman CH, Carrau RL, Spiro RM, Tyler-Kabara E, Kassam AB (2007) Corridor surgery: the current paradigm for skull base surgery. *Childs Nerv Syst* 23: 377–384.

Porter RW, Detwiler PW, Spetzler RF, Lawton MT, Baskin JJ, Derksen PT, Zabramski JM (1999) Cavernous malformations of the brainstem: Experience with 100 patients. *J Neurosurg* 90: 50–58.

Qian H, Lin S, Zhang M, Cao Y (2012) Surgical Management of Intraventricular Central Neurocytoma: 92 Cases. *Acta Neurochirurgica* 154: 1951-1960.

Rak R, Sekhar LN, Stimac D, Hechl P (2004) Endoscopeassisted microsurgery formicrovascular compression syndromes. *Neurosurgery* 54: 876-881.

Rhoton AL Jr (2000a) The cerebellopontine angle and posterior fossa cranial nerves by the retrosigmoid approach. *Neurosurgery* 47: 93-129.

Rhoton AL Jr (2000b) The farlateral approach and its transcondylar, supracondylar, and paracondylar extensions. *Neurosurgery* 47: 195–209.

Rogers CL, Shetter AG, Fiedler JA, Smith KA, Han PP, Speiser BL (2000) Gamma knife radiosurgery for trigeminal neuralgia: The initial experience of The Barrow Neurological Institute. *Int J Radiat Oncol Biol Phys* 47: 1013-1019.

Safavi-Abbasi S, Di Rocco F, Bambakidis N, Talley MC, Gharabaghi A, Luedemann W, Samii M, Samii A (2008) Has management of epidermoid tumors of the cerebellopontine angle improved? A surgical synopsis of the past and present. *Skull Base* 18: 85–98.

Samii M, Gunther T, Iaconetta G, Muehling M, Vorkapic P, Samii A (2002) Microvascular decompression to treat hemifacial spasm: long-term results for a consecutive series of 143 patients. *Neurosurgery* 50: 712–718.

Samii M, Klekamp J, Carvalho G (1996a) Surgical results for meningiomas of the craniocervical junction. *Neurosurgery* 39: 1086–1194.

Samii M, Tatagiba M, Carvalho GA (2000) Retrosigmoid intradural suprameatal approach to Meckel's cave and the middle fossa: Surgical technique and outcome. *J Neurosurg* 92: 235–241.

Samii M, Tatagiba M, Piquer J, Carvalho GA (1996b) Surgical treatment of epidermoid cysts of the cerebellopontine angle. *J Neurosurg* 84: 14–19.

Samii M, Matthies C, Tatagiba M (1997) Management of vestibular schwannomas (acoustic neuromas): auditory and facial nerve function after resection of 120 vestibular schwannomas in patients with neurofibromatosis 2. *Neurosurgery* 40: 696-705.

Schroeder HW, Oertel J, Gaab MR (2004) Endoscope-assisted microsurgical resection of epidermoid tumors of the cerebellopontine angle. *J Neurosurg* 101: 227–232.

Sen CN, Sekhar LN (1990) An extreme lateral approach to intradural lesions of the cervical spine and foramen magnum. *Neurosurgery* 27: 197–204.

Shahinain HK, Eby JB, Ocon M (2004) Fully endoscopic excision of vestibular schwannomas. *Minim Invas Neurosurg* 47: 329–332.

Shahinian HK and Ra Y (2011) 527 fully endoscopic resections of vestibular schwannomas. *Minim Invasive Neurosurg* 54: 61–67.

Steiger HJ, Hanggi D, Stummer W, Winkler PA (2006) Custom-tailored transdural anterior transpetrosal approach to ventral pons and retroclival regions. *J Neurosurg* 104: 38–46.

Stein BM, Leeds NE, Taveras JM, Pool JL (1963) Meningiomas of the foramen magnum. *J Neurosurg* 20:740–751.

Sun T, Saito S, Nakai O, Ando T (1994) Long-term results of microvascular decompression for trigeminal neuralgia with reference to probability of recurrence. *Acta Neurochir (Wien)* 126: 144-148.

Tamaki N, Hara Y, Takaishi Y, Shimada S (2001) Angled rigid neuroendoscope for continuous intraoperative visual monitoring: technical note. *J Clin Neurosci* 8: 148-150.

Tatagiba M, Matthies C, Samii M (1996a) Microendoscopy of the internal auditory canal in vestibular schwannoma surgery. *Neurosurgery* 38: 737–740.

Tatagiba M, Rigante L, Filho PM, Ebner FH, Roser F (2015) Endoscopic-Assisted Posterior Intradural Petrous Apicectomy in Petroclival Meningiomas: A Clinical Series and Assessment of Perioperative Morbidity. *World Neurosurg* 84: 1708-1718.

Tatagiba M, Roser F, Hirt B, Ebner FH (2014) The retrosigmoid endoscopic approach for cerebellopontine-angle tumors and microvascular decompression. *World Neurosurg* 82: 171-176.

Tatagiba M, Samii M, Matthies C, Vorkapic P (1996b) Management of petroclival meningiomas: a critical analysis of surgical treatment. *Acts Neurochir Suppl* 65: 92-94.

Tatli M, Satici O, Kanpolat Y, Sindou M (2008) Various surgical modalities for trigeminal neuralgia: literature study of respective long-term outcomes. *Acta Neurochir (Wien)* 150: 243-55.

Teo C, Nakaji P, Mobbs RJ (2006) Endoscope-Assisted Microvascular Decompression for Trigeminal Neuralgia. *Neurosurgery* 59: 489-490.

Tew JM Jr (1999) M. Gazi Yasargil: Neurosurgery's man of the century. *Neurosurgery* 45: 1010-1014.

Uluç K, Kujoth GC, Başkaya MK (2009) Operating microscopes: past, present, and future. *Neurosurg Focus* 27:E4.

Van Rompaey J, Bush C, McKinnon B, Solares AC (2013) Minimally invasive access to the posterior cranial fossa: an anatomical study comparing a retrosigmoidal endoscopic approach to a microscopic approach. *J Neurol Surg A Cent Eur Neurosurg* 74: 1-6.

Wackym AP, King WA, Poe Dennis S, Meyer GA, Ojemann RG, Barker FG (1999) Adjunctive use of endoscopy during acoustic neuroma surgery. *Laryngoscope* 109: 1193-1201.

Yilmazlar S, Kocaeli H, Cordan T (2004) Brain stem stroke associated with epidermoid tumours: report of two cases. *J Neurol Neurosurg Psychiatry* 75: 1340-1342.

Yong RL, Westerberg BD, Dong C, Akagami R (2008) Length of tumor-cochlear nerve contact and hearing outcome after surgery for vestibular schwannoma. *J Neurosurg* 108: 105-110.

Yoshida K, Kawase T (1999) Trigeminal neurinomas extending into multiple fossae: surgical methods and review of the literature. *J Neurosurgery* 91: 202-211.

Yuguang L, Chengyuan W, Meng L, Shugan Z, Wandong S, Gang L (2005) Neuroendoscopic anatomy and surgery of the cerebellopontine angle. *J Clin Neurosci* 12: 256-260.

ABSTRACT:

Objective:

To perform a risk assessment of endoscope-assisted microsurgery via transcranial approaches for posterior fossa lesions.

Methods:

We evaluated 85 patients whom underwent endoscope-assisted surgery for various pathologies of the posterior fossa via transcranial approaches from February 2010 till March 2015 in our Department. Retrospectively we analyzed the patient charts, operating reports, pre- and postoperative imaging, intraoperative video recordings, ICU charts, and follow-up data. We focused in particular on morbidity and mortality due to the endoscopic procedure.

All surgeries were performed combining microscope (Pentero OPMI, Karl Zeiss, Oberkochen) and the rigid endoscope (0°, 30°, 45° optics, Karl Storz, Tuttlingen). The angled optics always introduced under direct microscopic control. Continuous intraoperative neuromonitoring is standard in our Department for procedures in the posterior fossa.

Results:

The mean age of patients was 47.24 ± 13.99 years; 48 were women, 37 men. The pathologies treated were: Vestibular schwannoma (40), Epidermoid cyst (17), Posterior circulation aneurysm (6), Chordoma (1), Chondrosarcoma (1), Meningioma (3), Trigeminal neuralgia (6), Trigeminal ganglion inflammation (1), Trigeminal neurinoma (1), Fourth ventricle ependymoma (3), Brainstem cavernoma (1), Vagus neurinoma (1), Brain stem glioma (1), CSF fistula (1), Foramen magnum lesions (2), Hemifacial spasm (1).

We operated through the following approaches: lateral suboccipital (72 cases), median suboccipital (8 cases), pterional (3cases), far lateral (1 case), subtemporal (1 case).

Complications:

22 cases of cranial nerve injury: 1 case of dysphagia, 1 case of abducens paralysis, 1 case of trochlear paralysis, 19 cases of facial palsy. All deficits were temporary and recovered in the follow-up besides the trochlear lesion and one case of facial palsy which needed a sural graft. Further, occurred 2 cases of postoperative infection, 4 cases of CSF fistula, 1 case of vascular insult (PICA insult). The mortality rate was zero.

Regarding the use of the endoscope, no thermal CN injury occurred. In one case the trochlear nerve was injured mechanically due to the endoscope.

Conclusion:

The endoscope helps to explore hidden areas of posterior fossa minimizing drilling and retraction of neurovascular and brain structures. Using the endoscope in addition to the microscope enables a safer surgery in posterior fossa even with lesions not visible in a straight line with the microscopic view. The risks due to insertion of the endoscope under microscopic guidance are minimal. We expect that new advancement in the endoscopic instrument will enable more improvement in the endoscopic-assisted surgery.

Zusammenfassung (Schlussfolgerungen)

Es ist sehr wichtig zu beachten, dass eine "sichere Operation" nur durch eine gute Sicht und Orientierung zu erreichen ist. Gute Belichtung, überlegene Beleuchtung in der Tiefe, bessere Feldvergrößerung und die Fähigkeit, die versteckten Ecken zu erforschen und hinter Strukturen zu blicken, müssen erfüllt sein, um die ideale Sicht zu erhalten.

Trotz des großen Wertes des Mikroskops bei der Beleuchtung und Vergrößerung der regionalen Anatomie in den mikrochirurgischen Verfahren auf dem Gebiet der Schädelbasischirurgie ist es immer noch ein Hindernis, der Suche nach einem "perfekten visuellen Werkzeug" insbesondere bei schwierigen hinteren Schädelbasisläsionen gerecht zu werden. Inzwischen war die Suche nach einem alternativen oder adjuvanten visuellen Werkzeug eine Pflicht. Als visuelles Werkzeug kann das Mikroskop allein nicht alle Informationen liefern.

Einerseits hat das Endoskop als visuelles Werkzeug viele Nachteile des Mikroskops gelöst. Andererseits kann nur von seiner Spitze aus gesehen werden. So entstand die Idee, die Eigenschaften dieser beiden Werkzeuge in einem einzigen Verfahren zu kombinieren. Durch die Anwendung des Endoskops in das Feld unter Direktsicht des Mikroskops "Endoskopische-assistierte Technik" kann die perfekte "Sicht und Orientierung" aller erhalten werden.

Wir empfehlen "Endoskopische-assistierte Technik" als sichere Vorgehensweise, um mit verschiedenen Situationen umzugehen, in denen die mikroskopische Betrachtungsweise nicht in der Lage war, uns ein vollständiges Bild zu liefern. Wir erwarten mehr Entwicklung und Fortschritte der endoskopischen Instrumente, die das Endoskop zusammen mit dem Mikroskop zu einem perfekten Werkzeug macht.

Acknowledgement

First and foremost, my great praise and sincere thanks should be submitted to **ALLAH**, the most gracious and the most merciful, for his kind continuous support to me, surpassing all the obstacles I faced and gave us the knowledge to think, believe, and worship. By the grace of **ALLAH**, this research work has been accomplished.

I would like to express my deep thanks, appreciation, and sincere gratitude to my **Prof. Dr. Marcos Tatagiba** Professor of Neurosurgery, Department of Neurosurgery, Eberhard Karls University Hospital, Tübingen, Germany for his close supervision, constant encouragement, guidance, and honest advice throughout this research work. He is considered my Father in Science.

Special Thanks to **Professor Dr. Ahmed Zohdi** (Cairo University, Egypt) for sparing no effort or time to guide and help me with valuable advice and helpful suggestions to finish this work.

This research was performed during my fellowship in the department of neurosurgery, Tübingen University, Germany. The fellowship was part of a cooperation program between the German Academic Exchange Service (**DAAD**) and the Egyptian Ministry of High Education.

I would like to express my sincere gratitude and special regards to **Prof. Dr. Florian Ebner**, Department of Neurosurgery, Eberhard Karls University Hospital, Tübingen, Germany for his extensive cooperation, great support, and generously helping me to complete my thesis. Sincere appreciation and deepest thanks from my deep heart to my big brother **Dr. Ahmed Rizk**, Neurosurgery Department, Trier, Germany for generously providing me with his time, valuable advice, and helpful suggestions.

My sincere thanks are also extended to **Dr. Rocio Evangelista Zamora**, Department of Neurosurgery, Eberhard Karls University Hospital, Tübingen, Germany for collection and editing the photos in this work.

Special thanks are owed to **Dr. Sasan Adib** Department of Neurosurgery, Eberhard Karls University Hospital, Tübingen, Germany for his valuable support.

I am also indebted by deep thanks to **Mrs. Susanne Efferenn** for her unlimited encouragement to finish my thesis.

Last, but not least I cannot find the words that express my appreciation, grateful and heartfelt gratitude to my father, **Eng. Ahmed Mourad**, lovely mother, and my brothers **Eng. Ibrahim**, and **Eng. Off. Mahmoud**, for their unending support in all aspects of life, unlimited and continuous encouragement, savior love, care and high motivation for finishing this work.

Finally, my thanks to my precious queen **Dr. Eman Saleh** and my princesses **Lulu** and **Emi**, for their kind dealings, real cooperation, and encouragement during execution of this work.

Without you, I wouldn't do it.

Mohammed

Aktueller Lebenslauf

Persönliche Informationen:

Vorname: Mohammed

Nachname: Mourad

Staatsangehörigkeit: Ägyptisch

Geburtsdatum: 01.10.1982

Aktuelle Position /Berufsfeld:

Klinischer Gastwissenschaftler ,Klinik für Neurochirurgie, Universitätsklinikum Tübingen.

Berufserfahrung:

Juli 2008 - August 2011: Assistentarzt für Neurochirurgie, Benha Universitätskliniken – Ägypten.

August 2011 - August 2012: Tutor für Neurochirurgie, Benha Universitätskliniken – Ägypten.

August 2012 bis zur Gegenwart: Assistant Dozent der Neurochirurgie, Benha Universitätskliniken – Ägypten.

November 2010 - April 2013: Assistentarzt für Neurochirurgie - Kairo kurative Institut - Heliopolis Krankenhaus.

November 2012- Mai 2013: Spezialist für Neurochirurgie, International Medical Center (IMC) - Kairo.

Mai 2014 bis zur Gegenwart: klinischer Gastwissenschaftler als DAAD Stipendiat unter der Leitung von Prof. Dr.med. Marcos Tatagiba. Klinik für Neurochirurgie, Universitätsklinikum Tübingen.

Bildung und Ausbildung:

*Gymnasium 1998, Qalyub High School, Qalyoub, Ägypten - Grade: 96%.

*Bachelor-Abschluss in Medizin und Chirurgie, Dezember 2006, Benha der Medizinischen Fakultät, Benha Universität - Grad: Sehr gut mit Auszeichnung.

*M.Sc. Abschluss in Allgemeinchirurgie -Juli 2011 - Benha der Medizinischen Fakultät, Benha Universität -Grad: Sehr gut.

Bezeichnung der Qualifikation M.Sc. 2008 - 2011 Thema über " Neurofibromatose von Hirnnerven ". Gut mit Auszeichnung Grad.